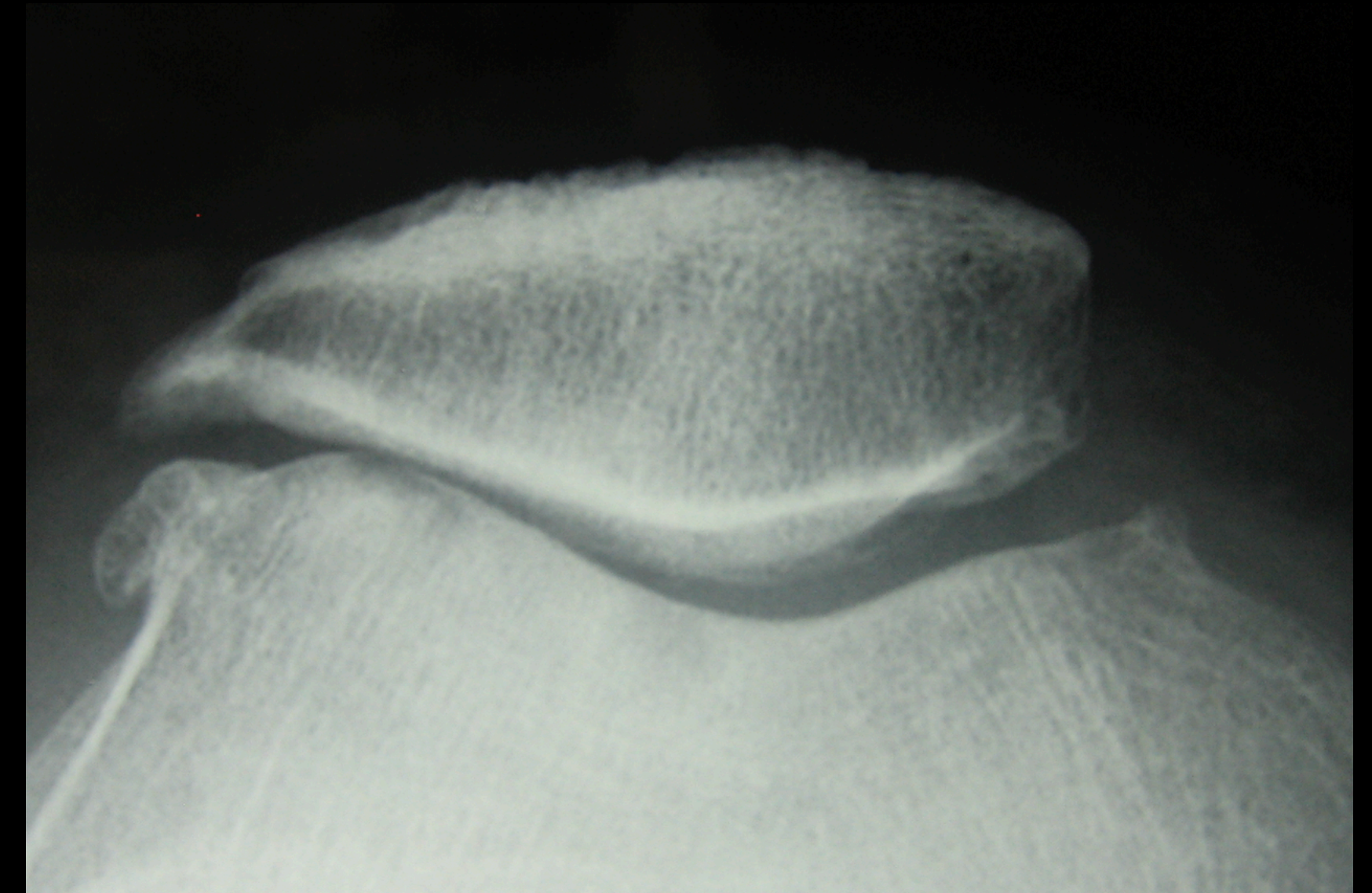


# **How I deal with cartilage and osteochondral defects in patellofemoral instability**

**Philippe Landreau, MD**  
**Consultant Orthopaedic Surgeon**  
**Orthocure & Mediclinic**  
**Dubai**  
**UAE**

# Cartilage injuries in PF instability

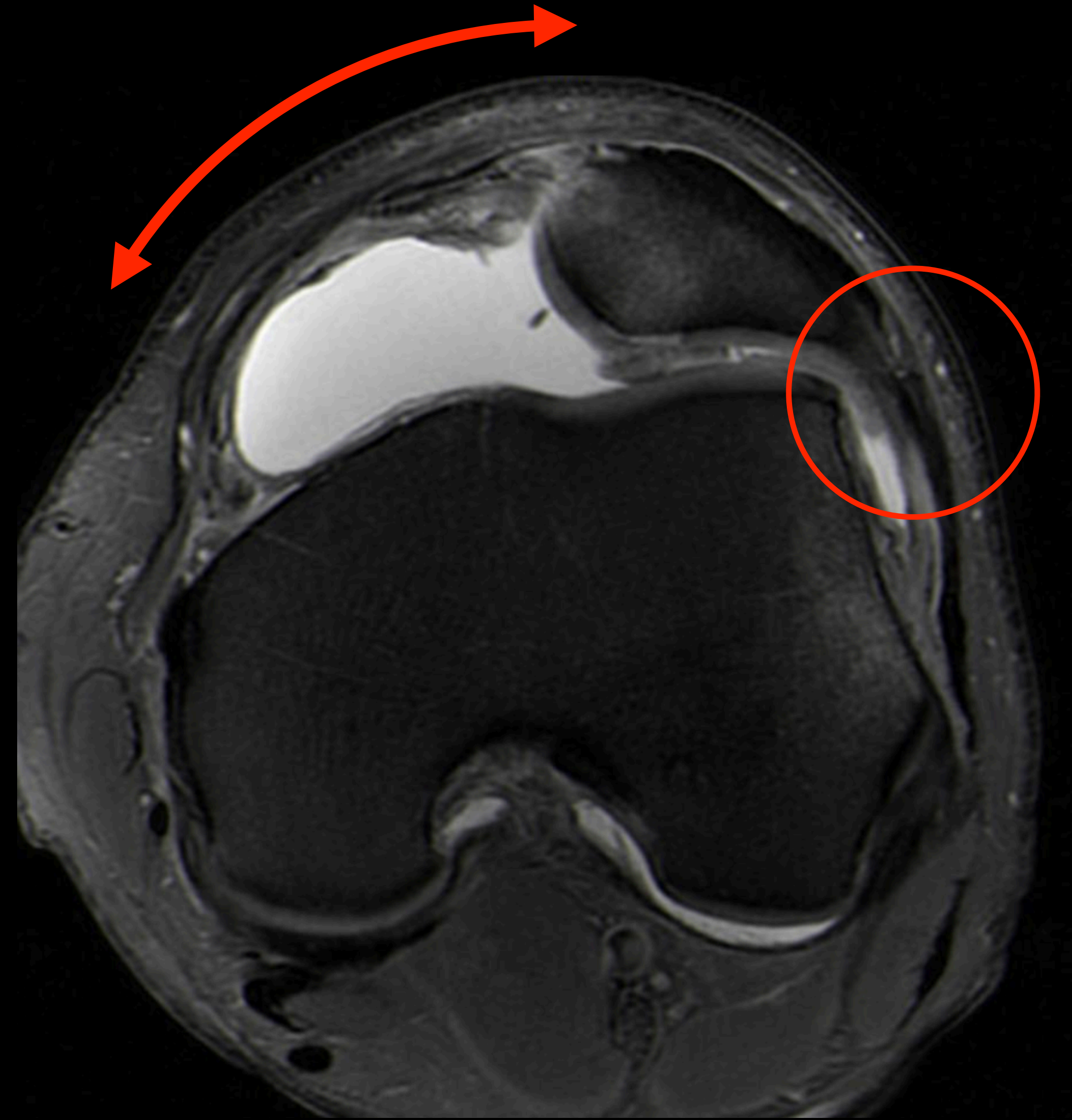
- Frequent problem in patellofemoral instability
- And ultimately, OA is the main problem if not treated
- “Prevention” is therefore the key point





# “Prevention”

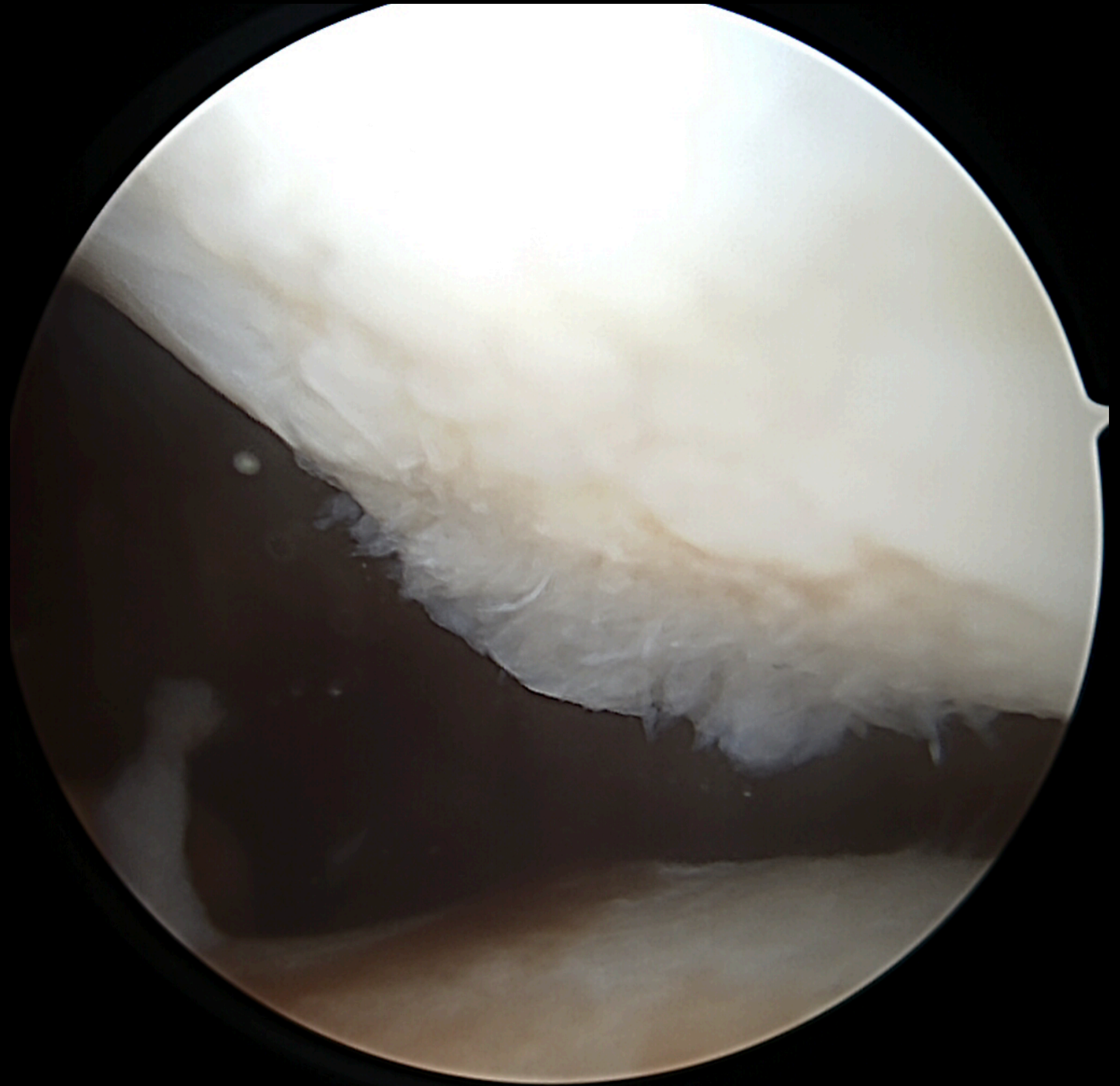
- **Correct the instability** and unload the zone of cartilage defect
- Do we have to treat the cartilage lesion?





## 2 scenarios

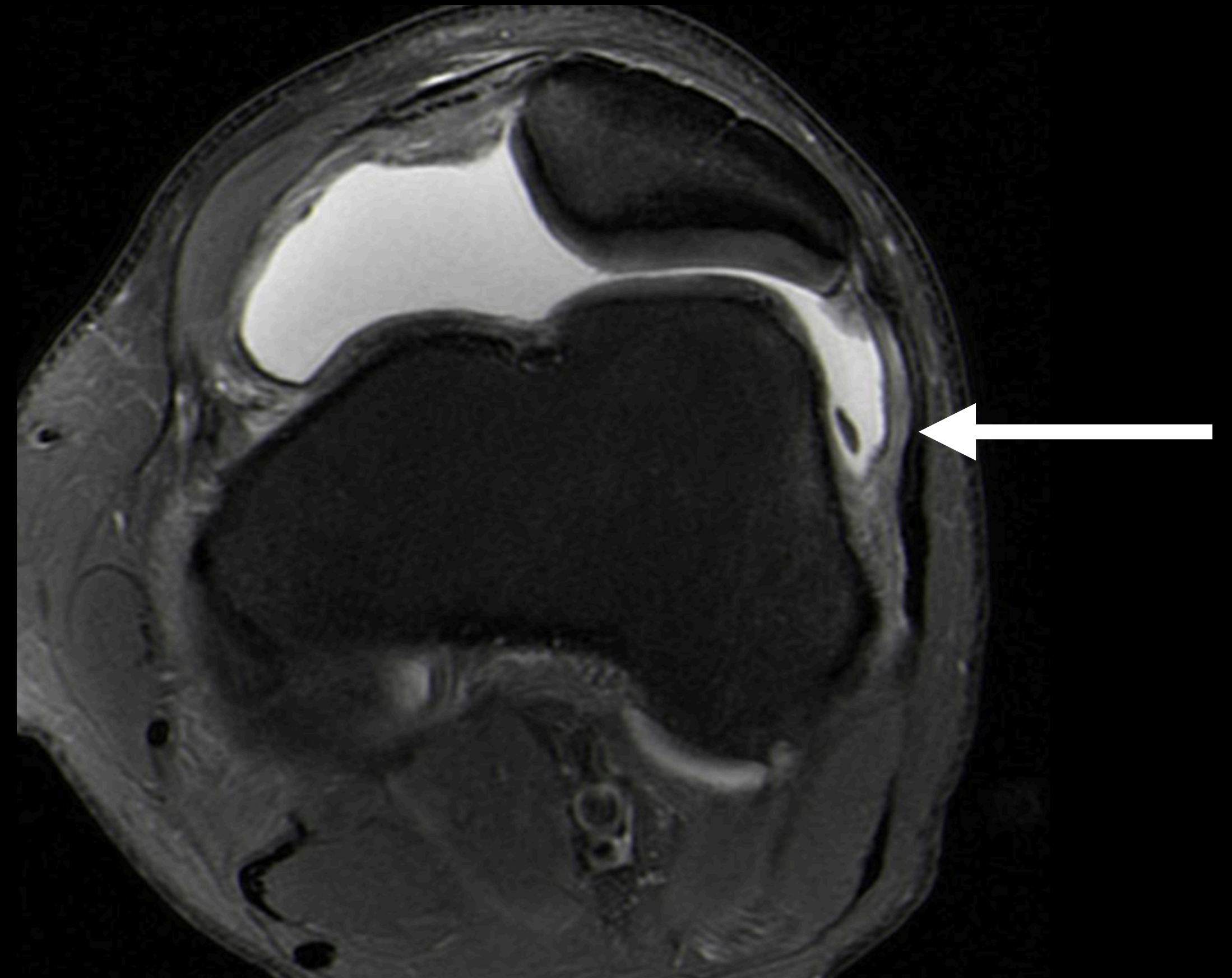
- **Acute**
- **Chronic**





# Acute cases

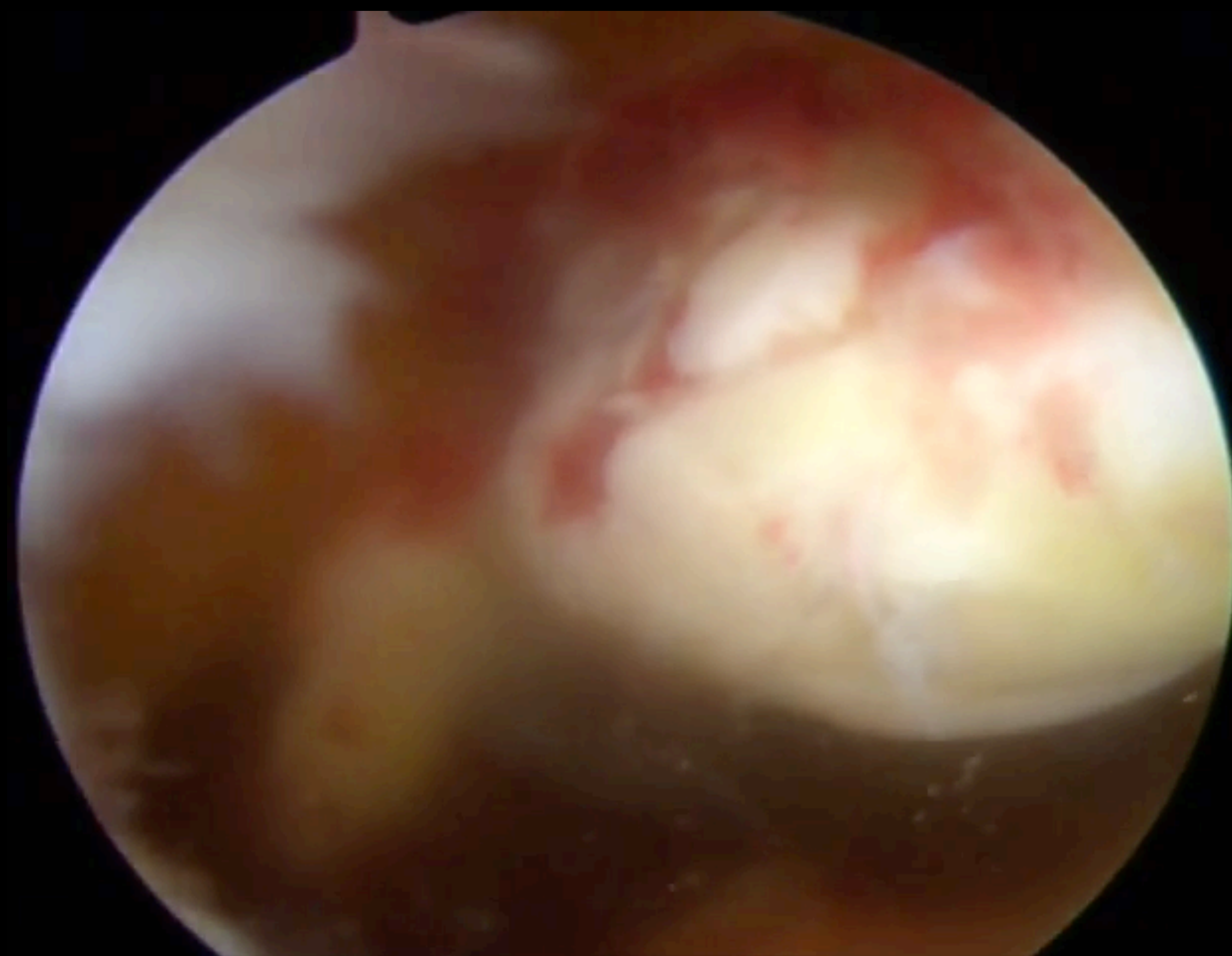
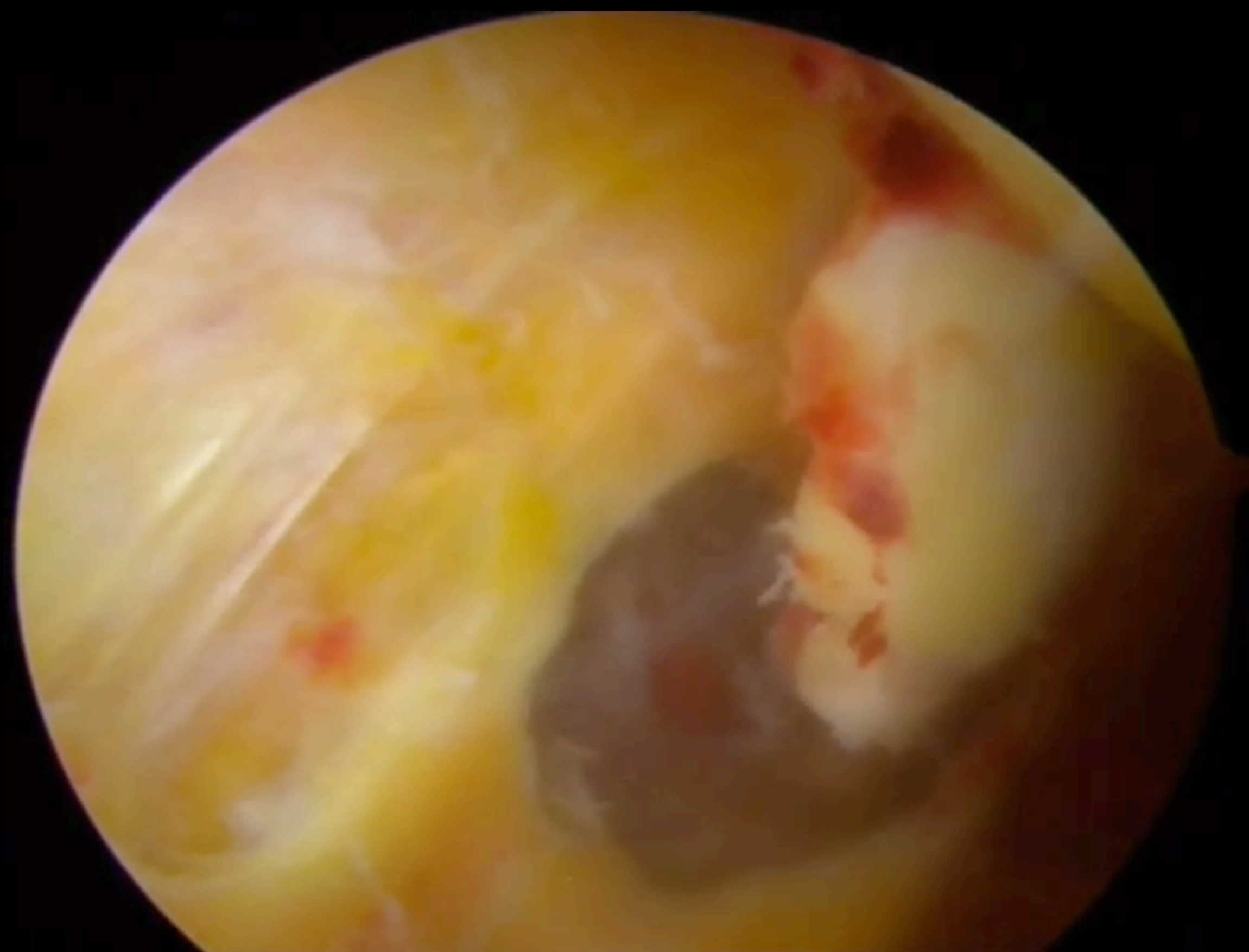
- Osteochondral defect, loose bodies





## **Acute cases: Osteochondral defect, loose bodies**

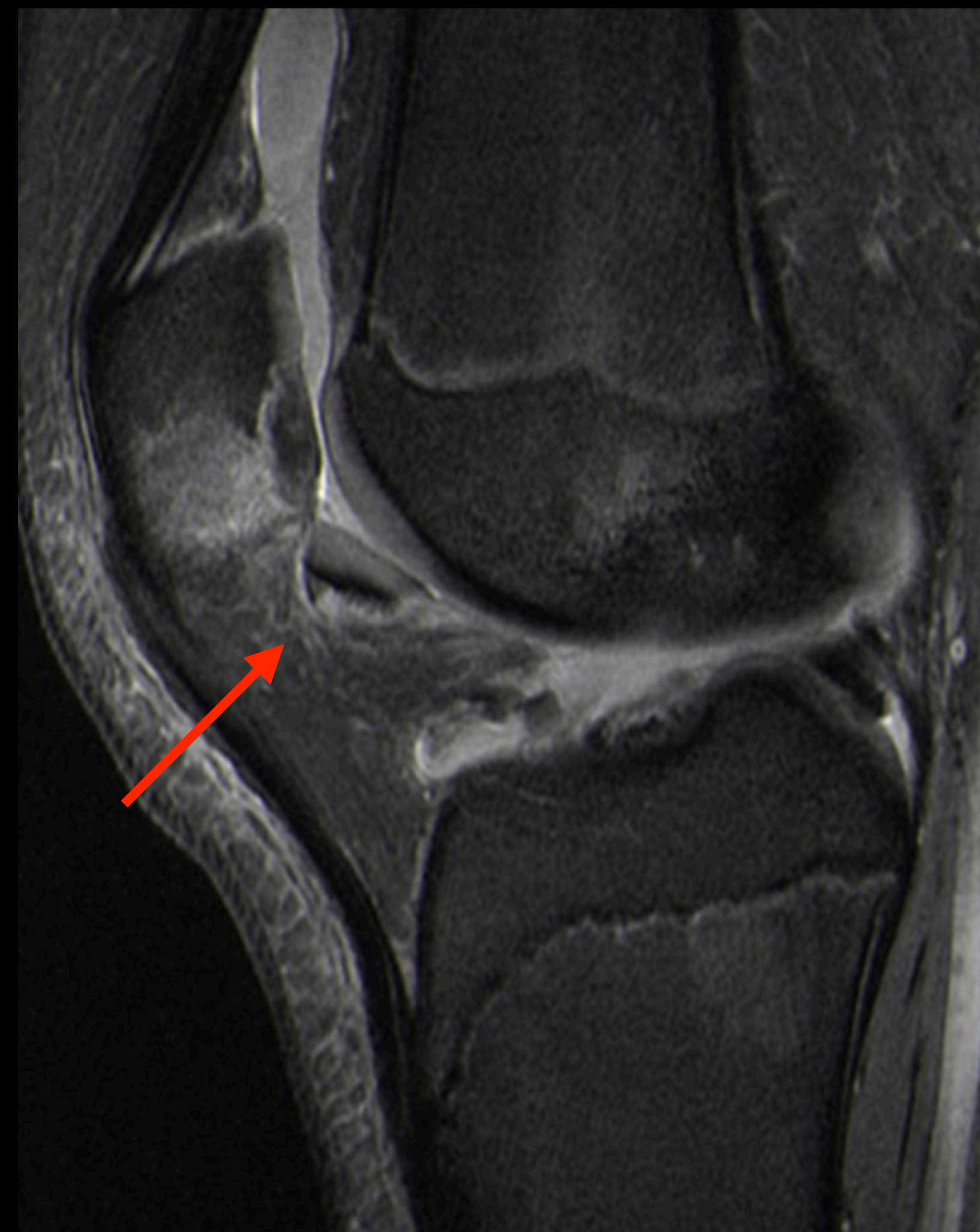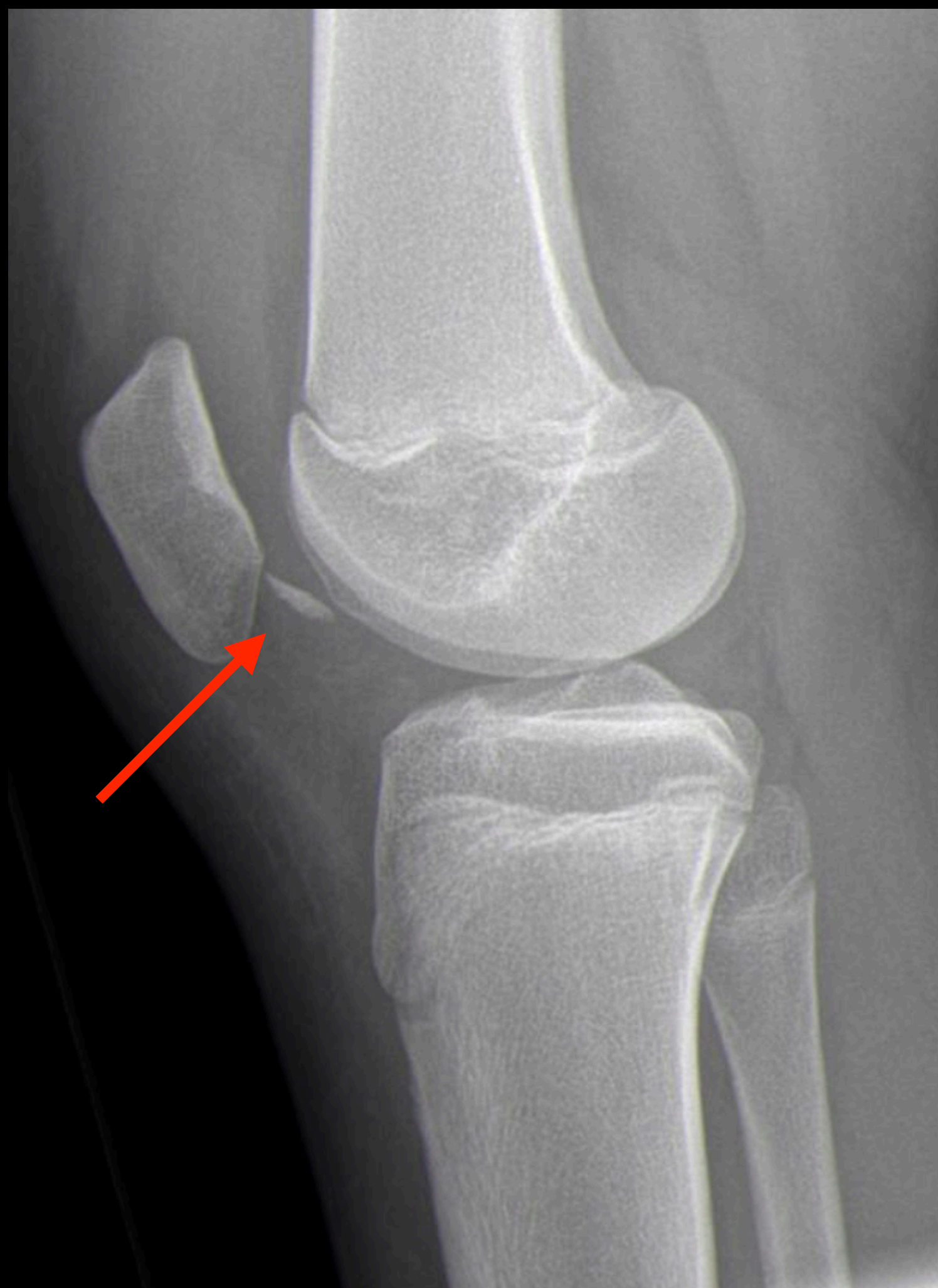
- If only chondral loose body, usually simple resection
- one of the justification for arthroscopy after first episode of instability is conservative treatment is the option



# **Acute cases: Osteochondral defect, loose bodies**

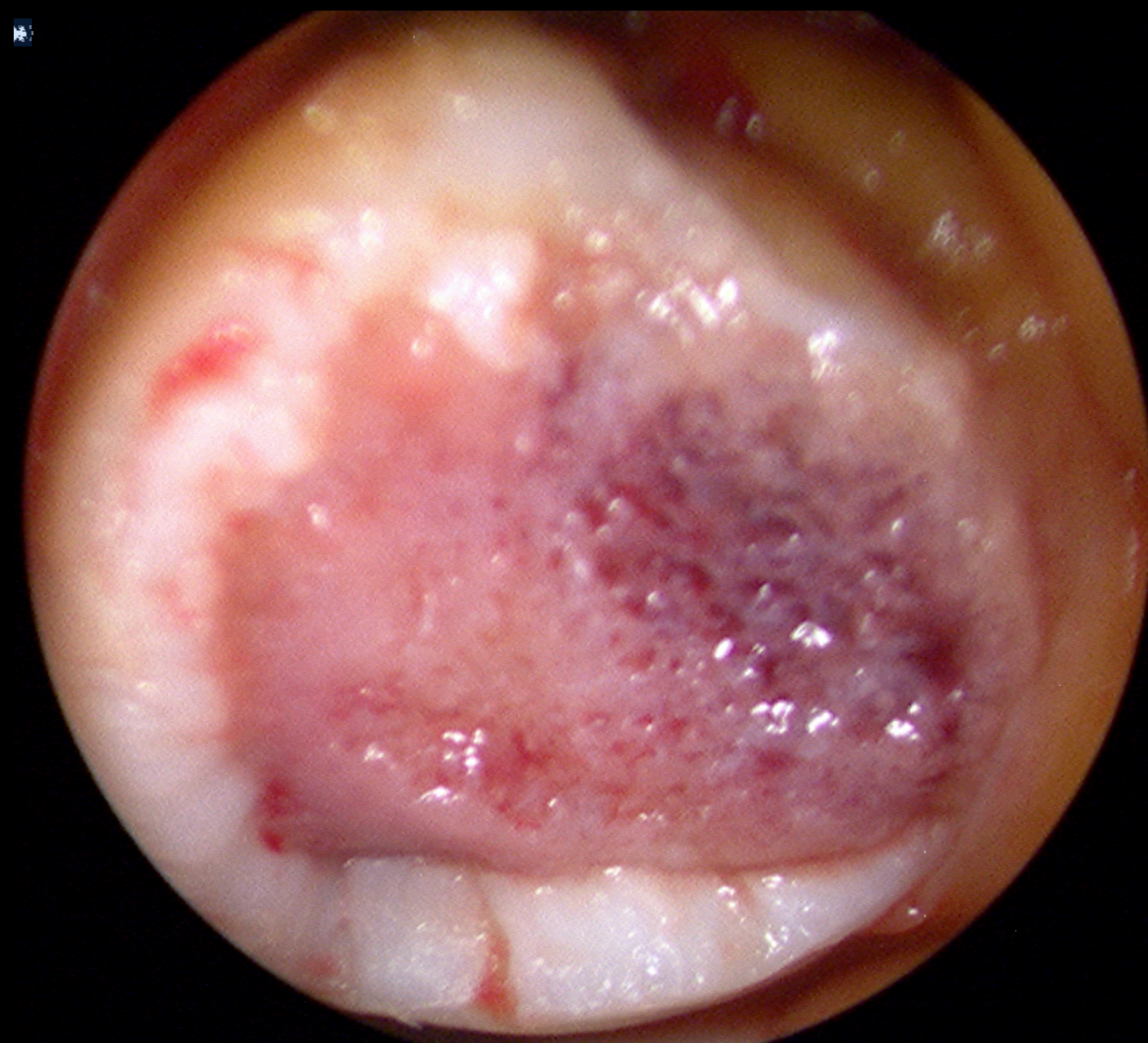
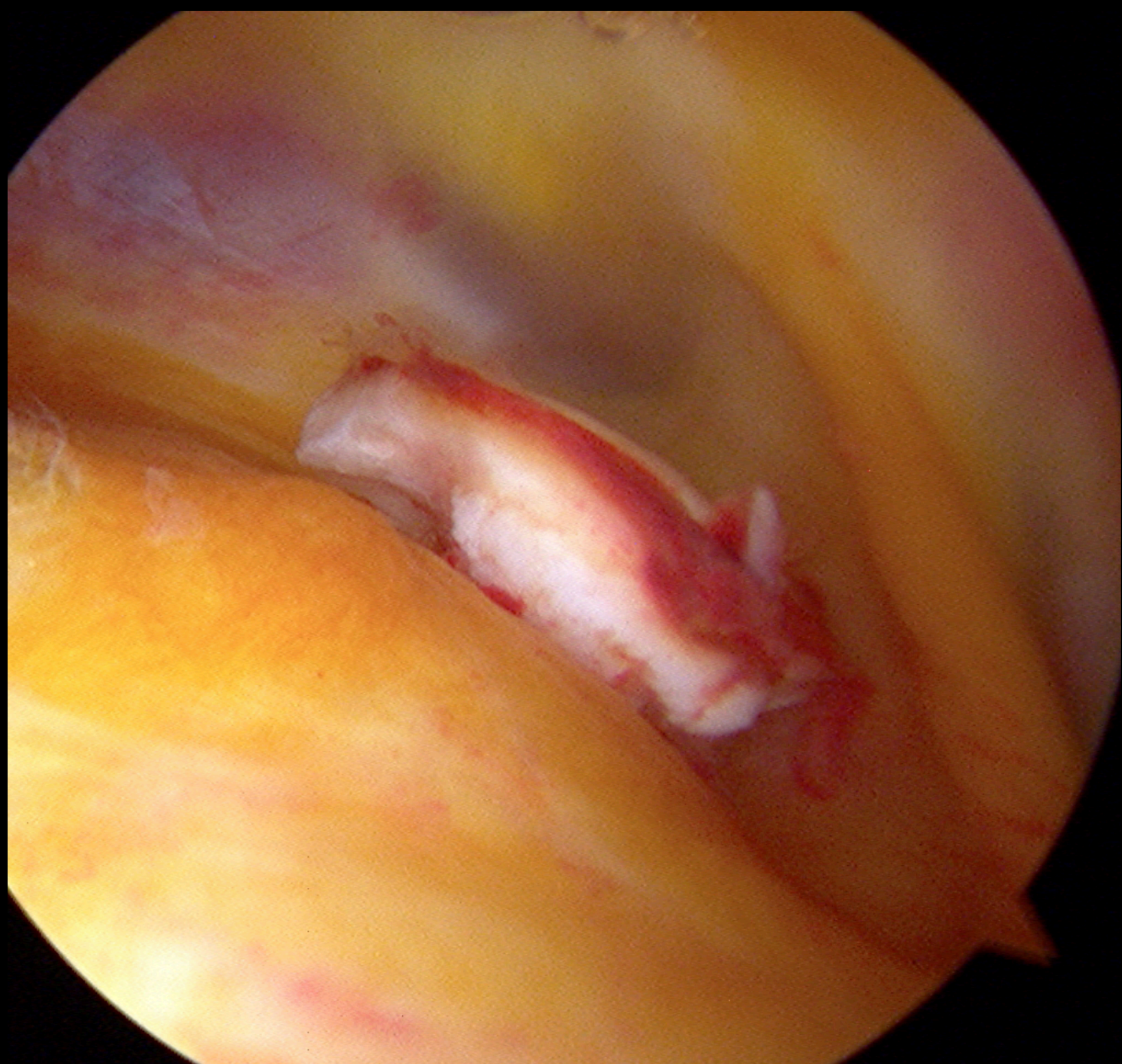
- If osteochondral fragment, fixation +/- combined with PF surgical correction.



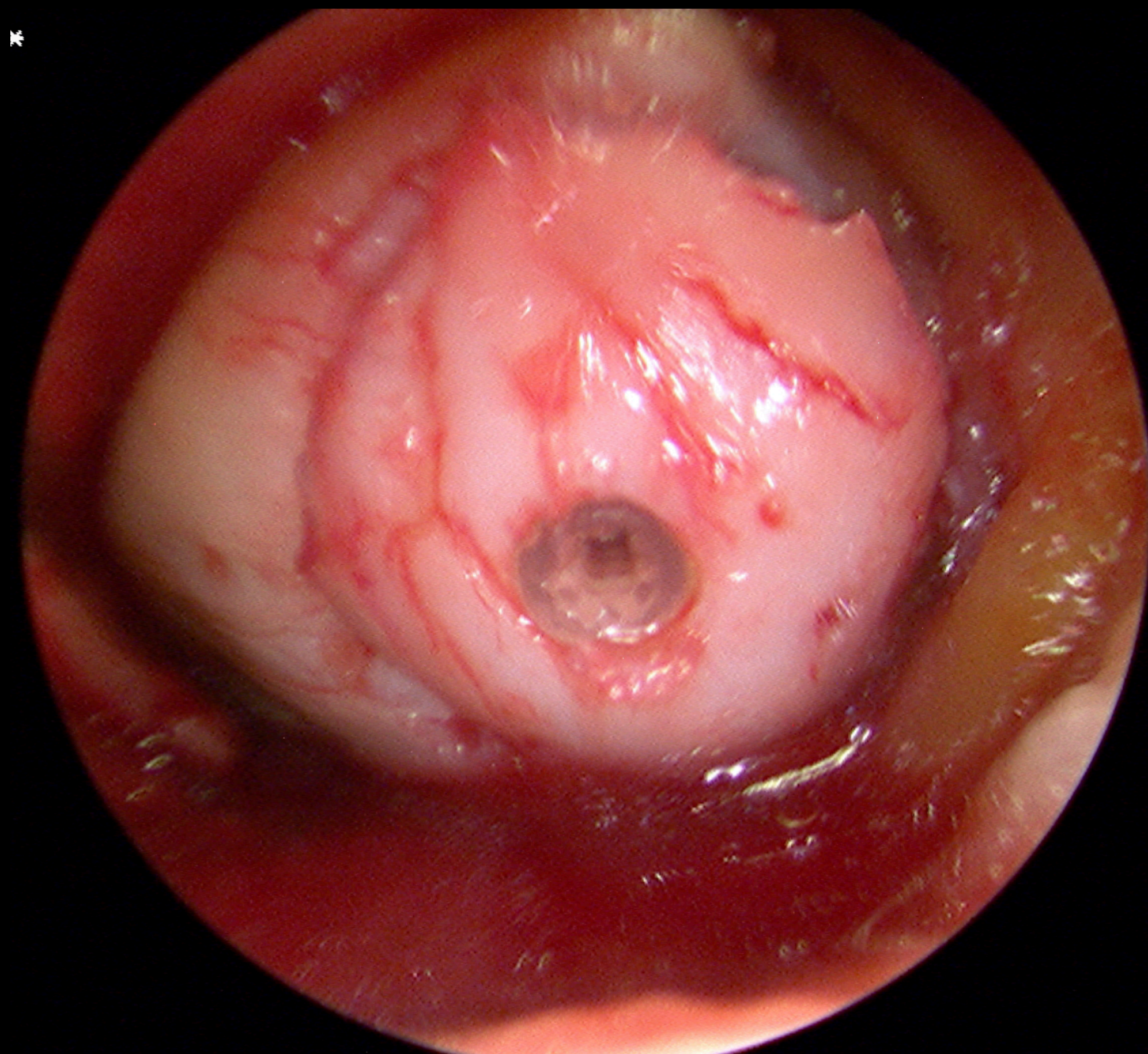
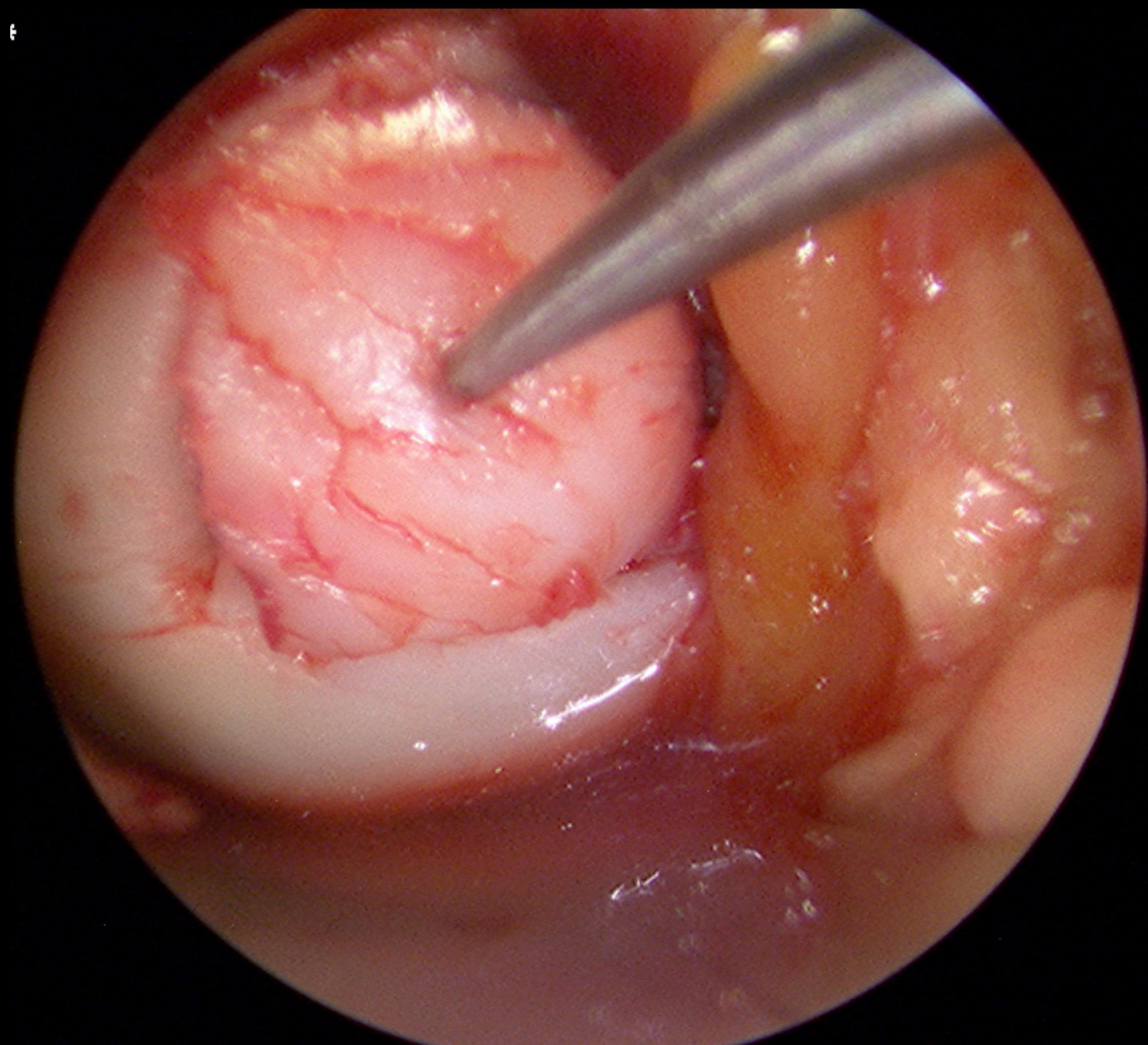


14 yo Female  
Patella dislocation  
First episode

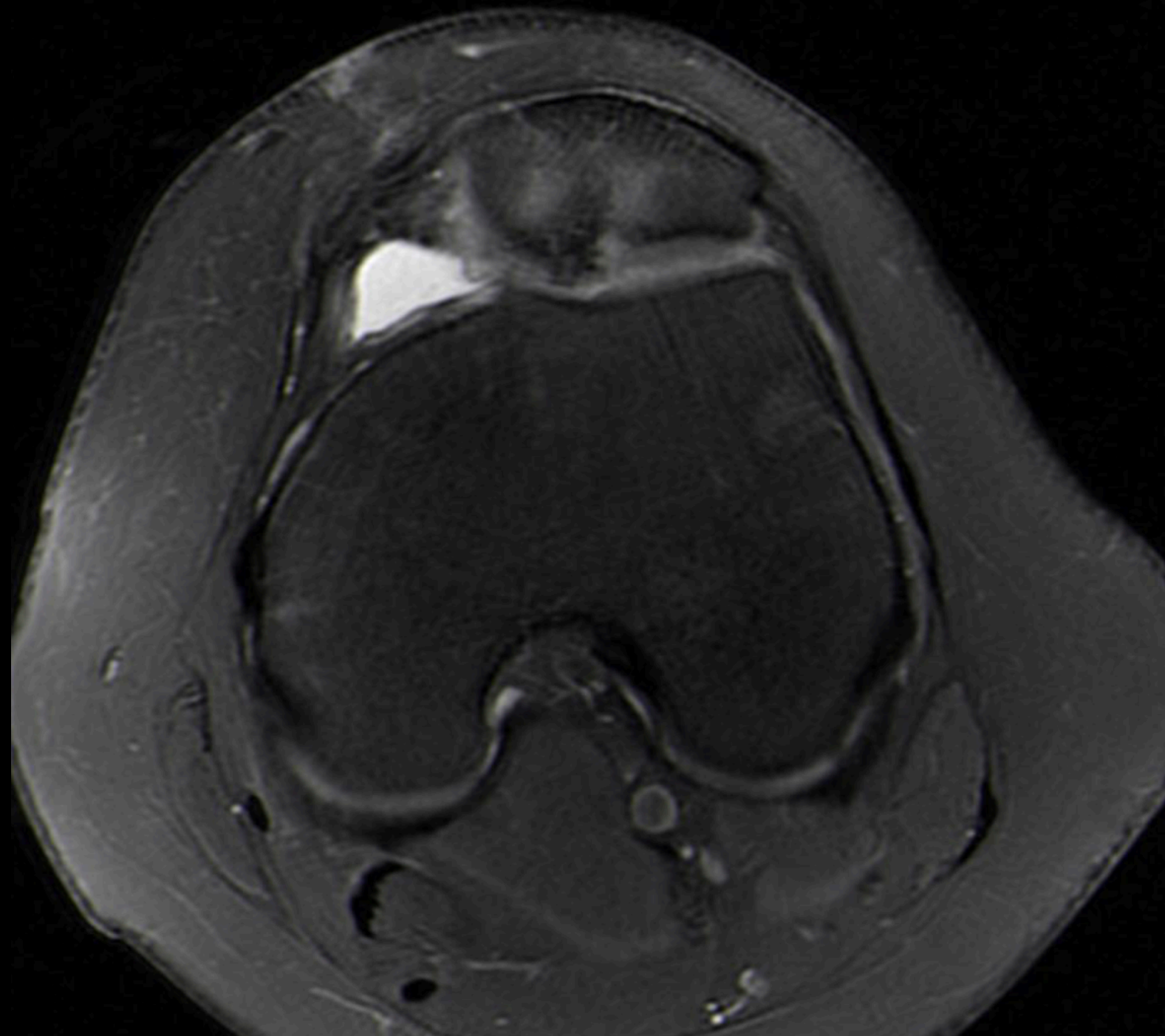




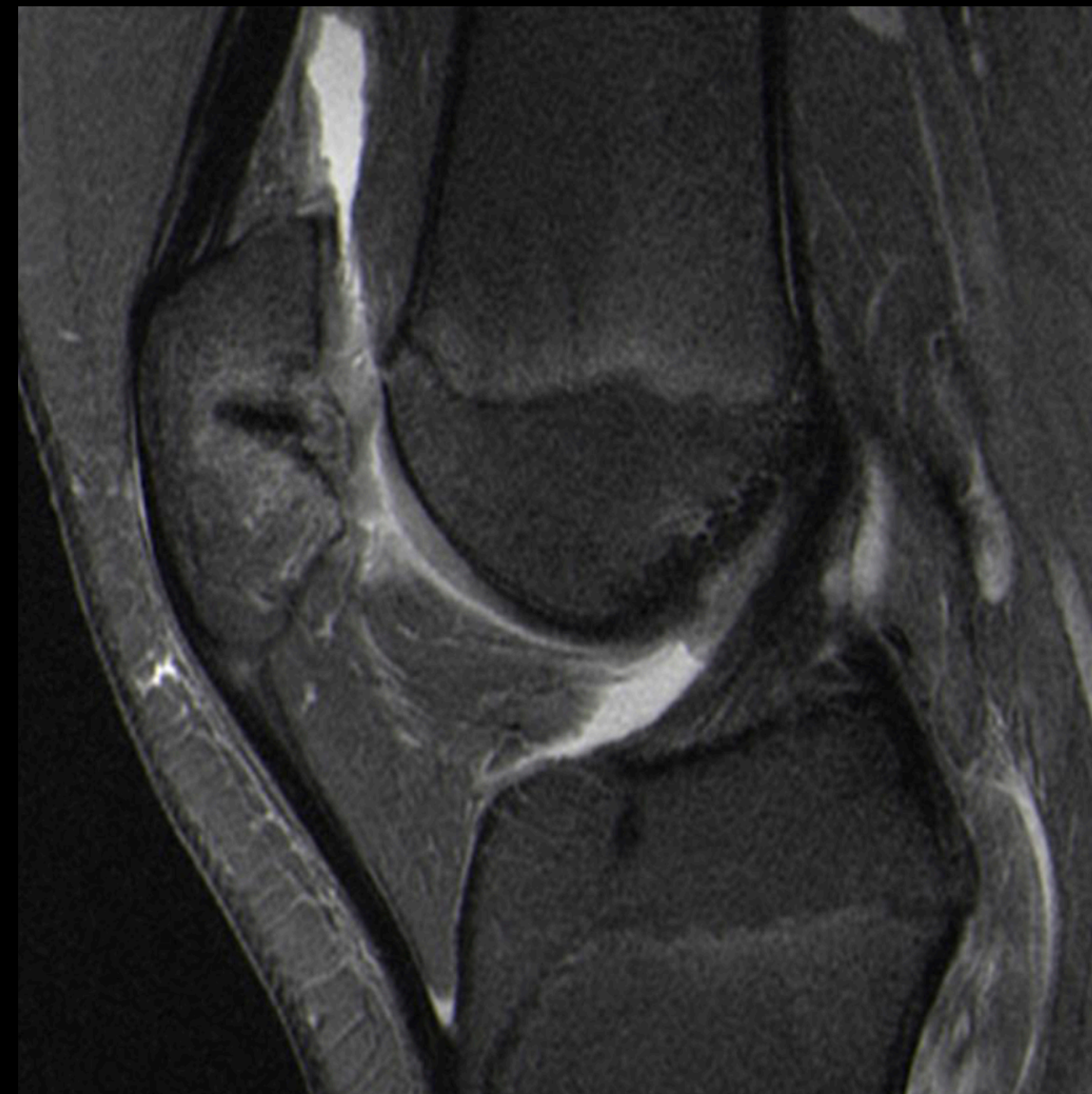
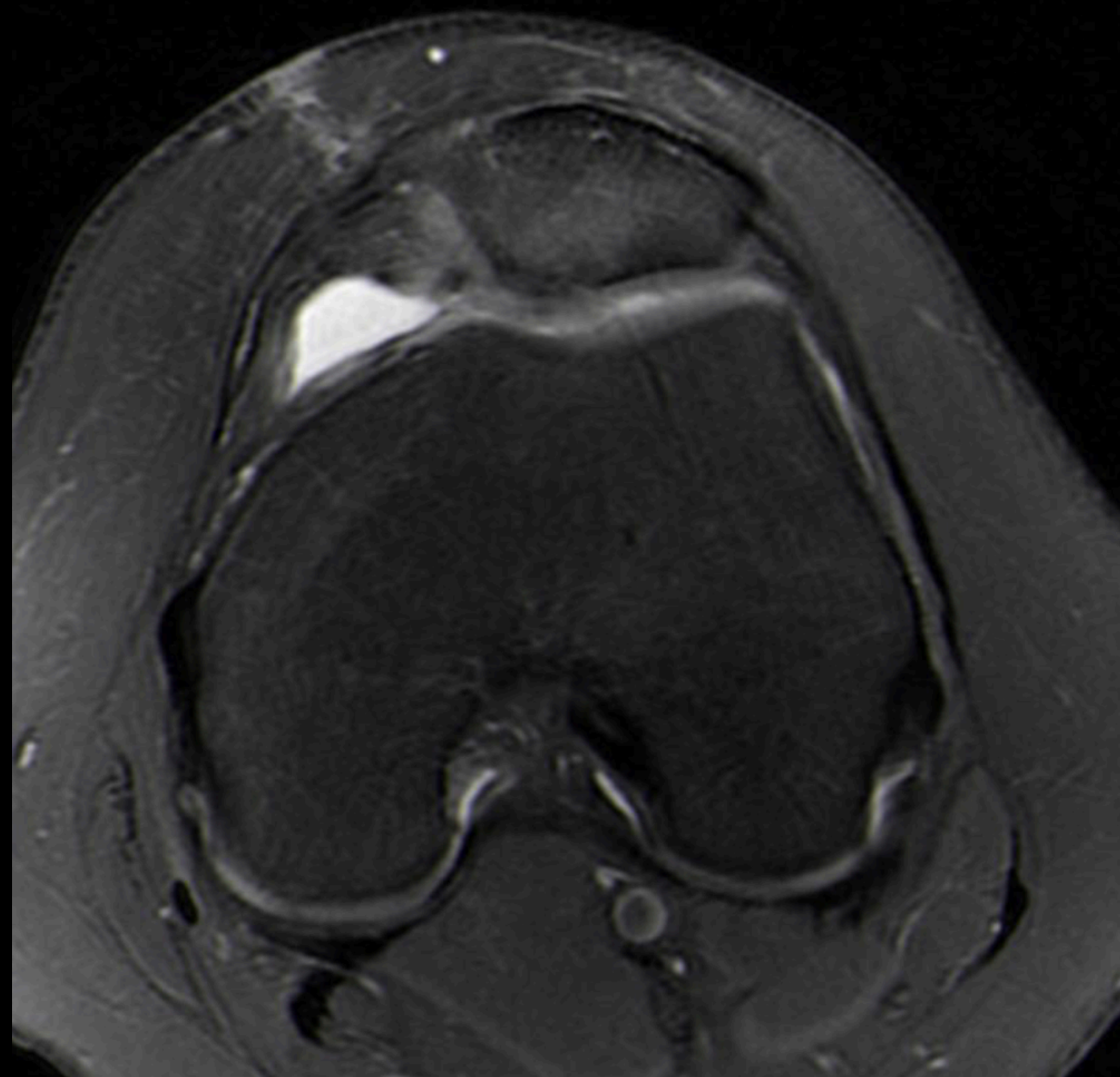




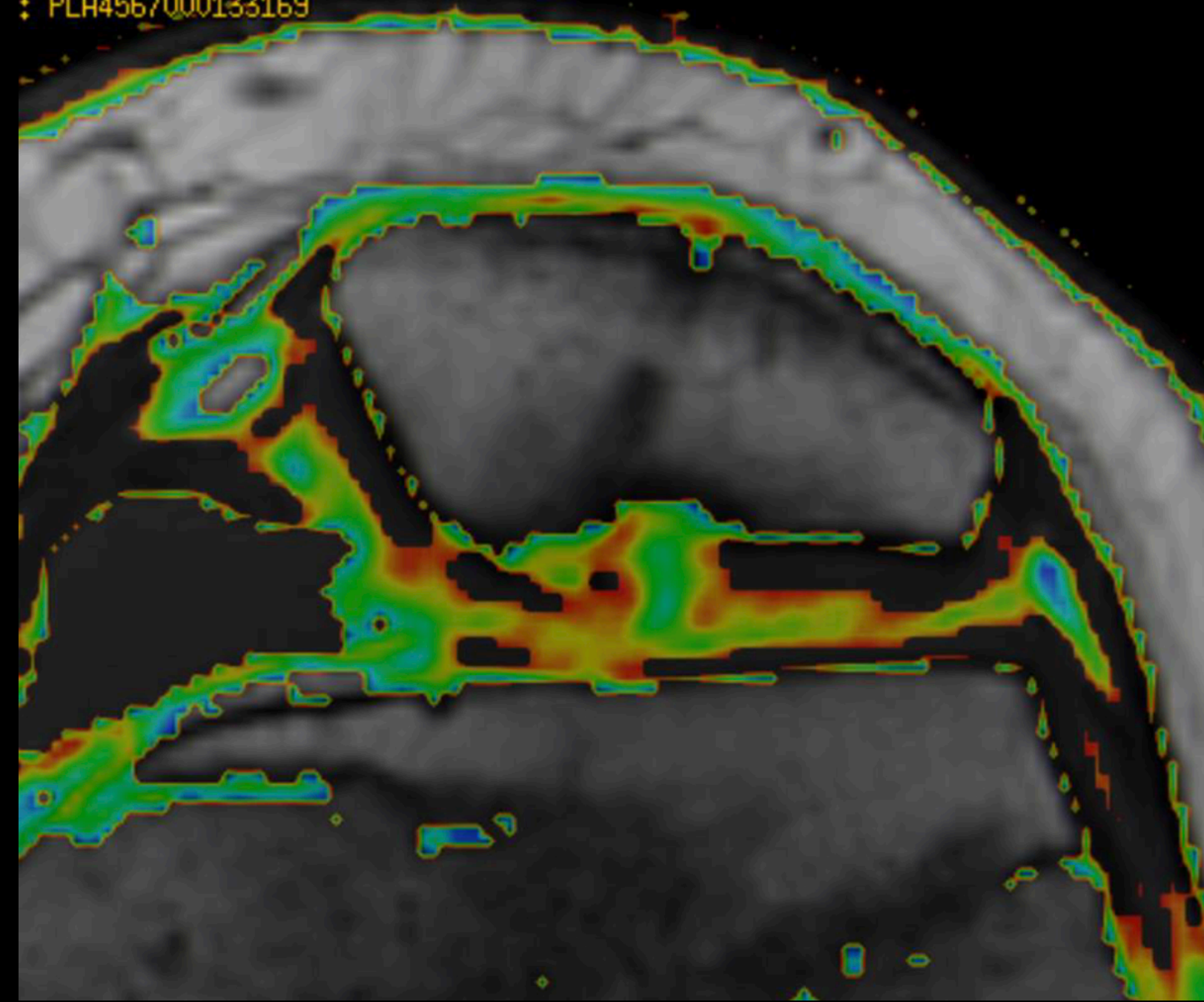




6 months



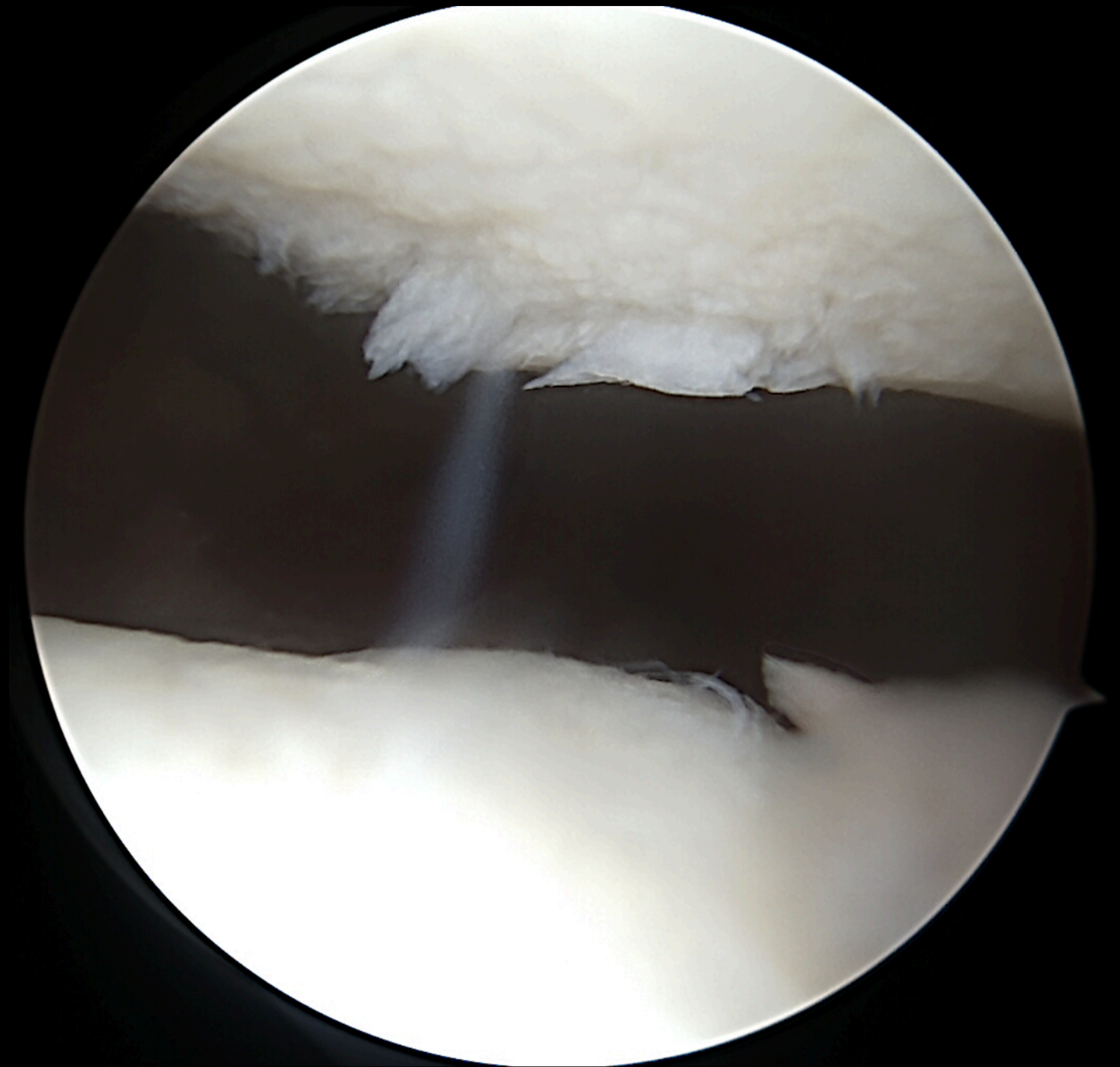
pt 21 2001  
: PLA4567000133169



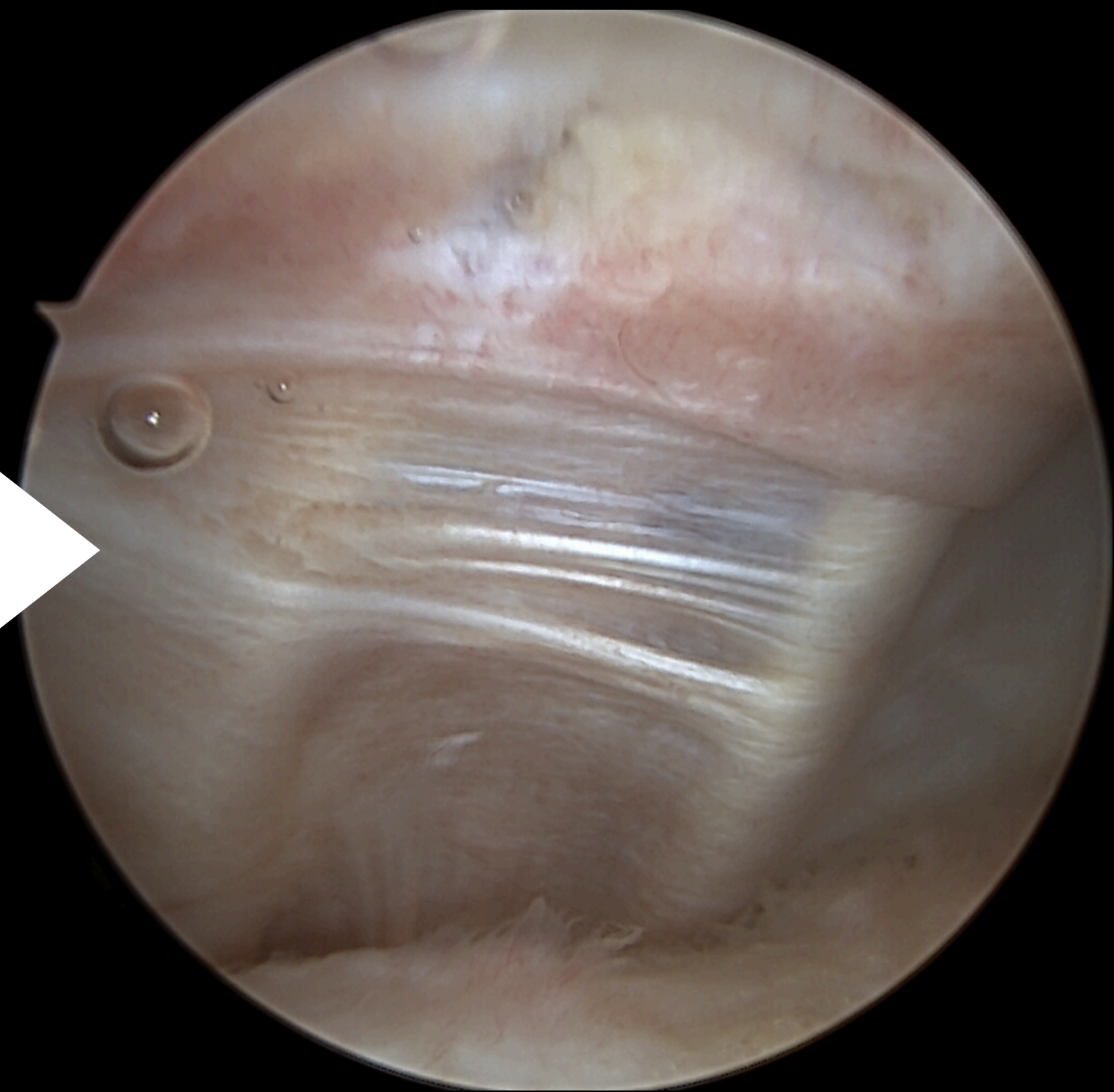

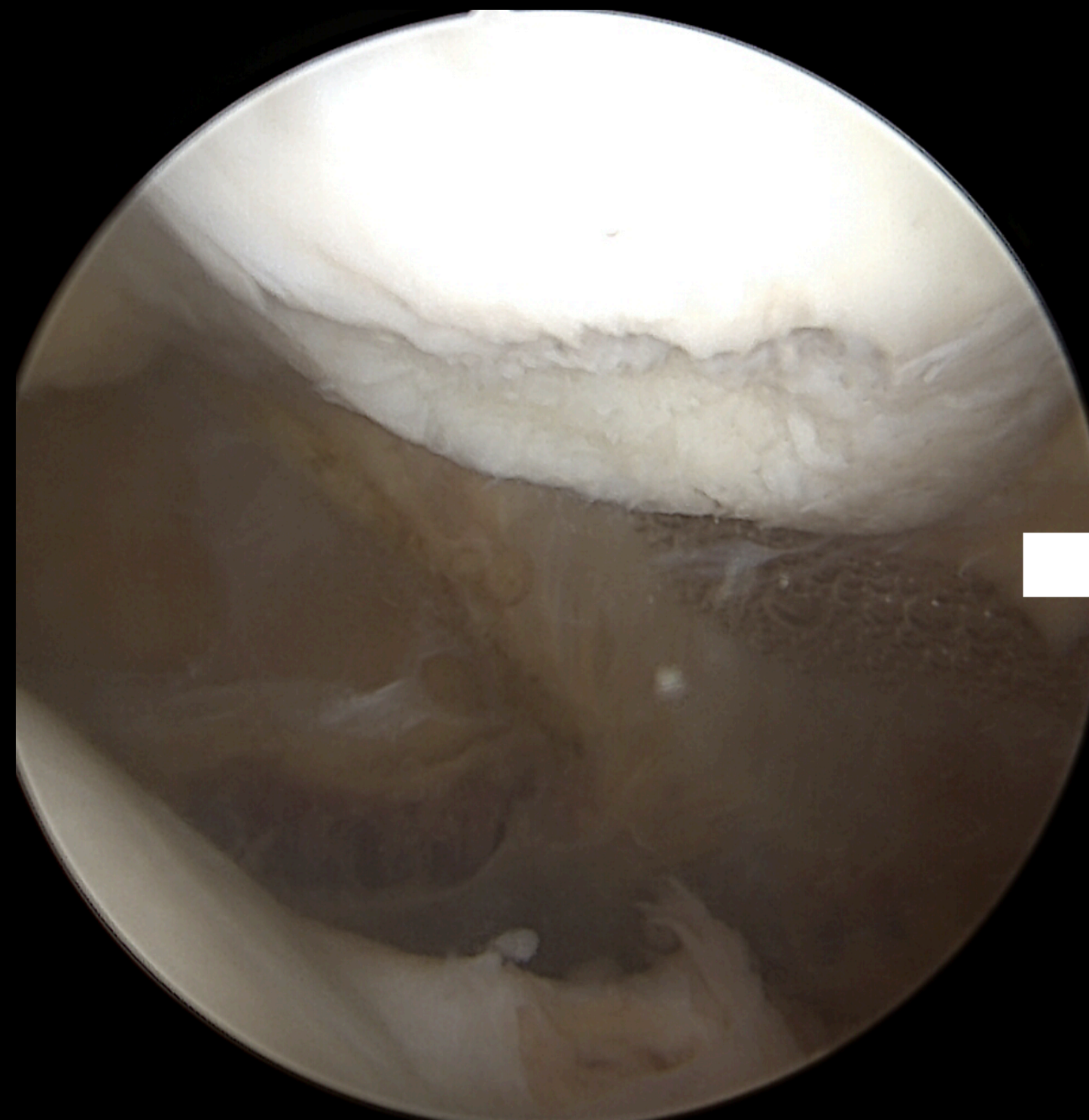

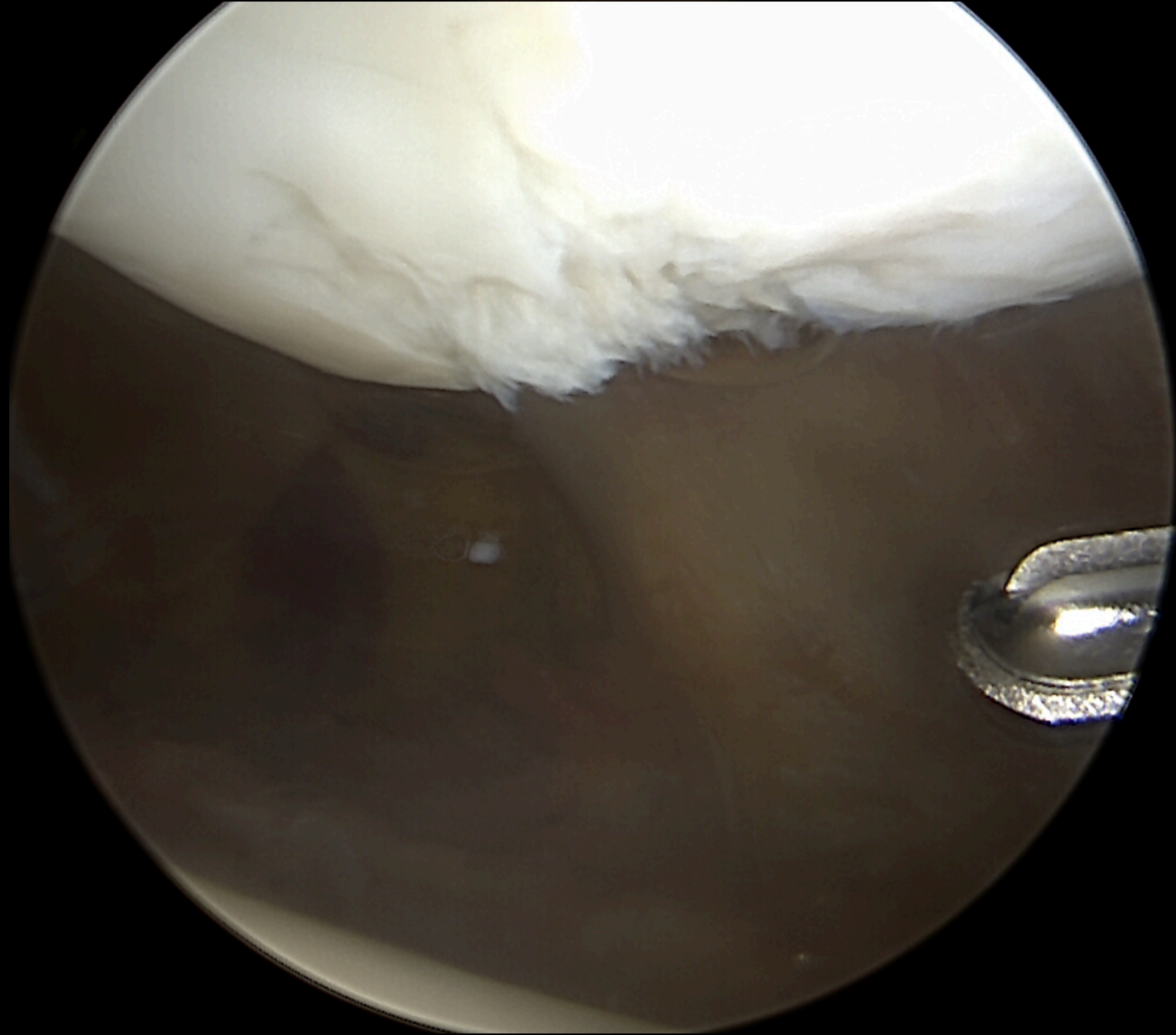
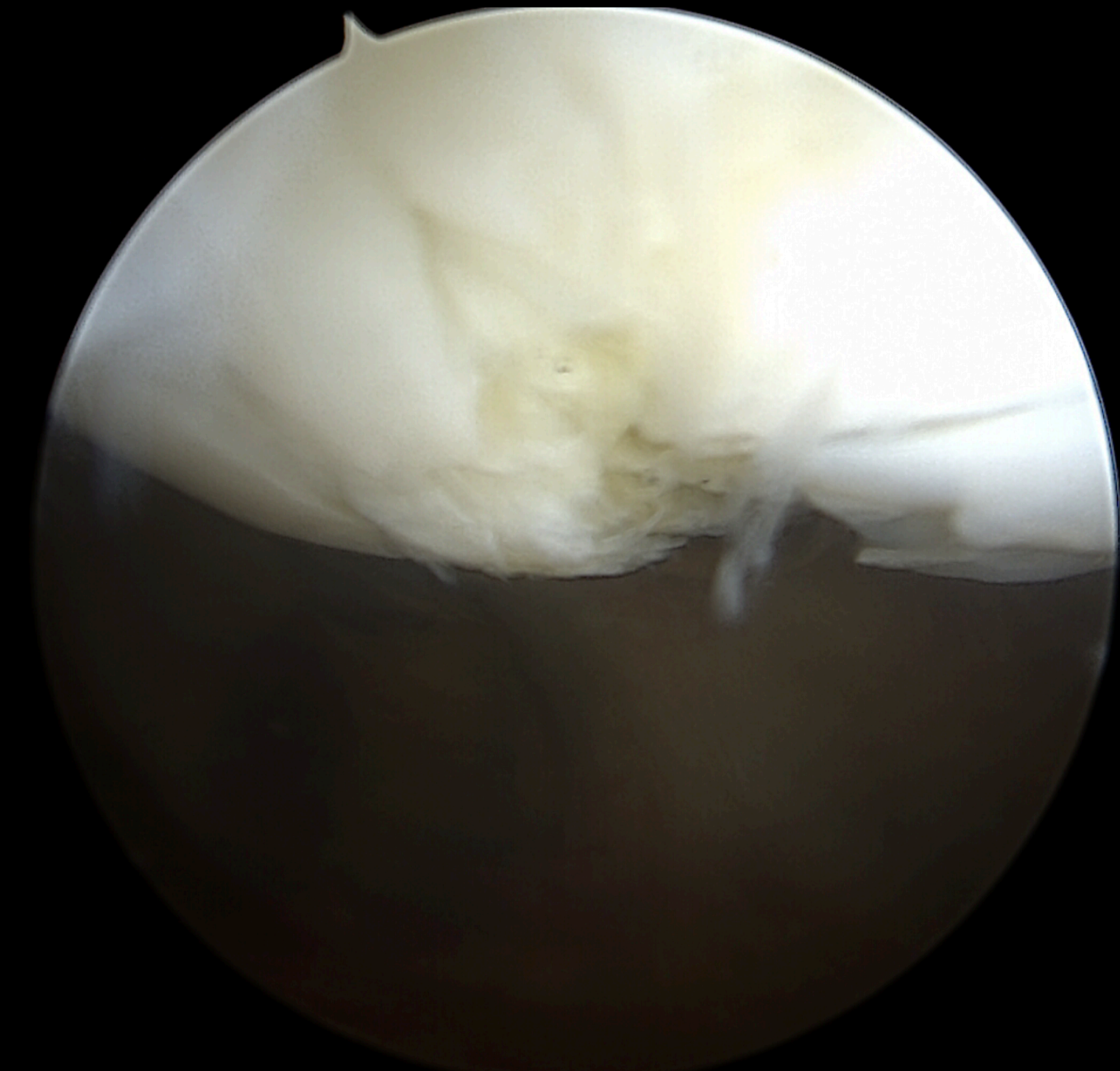


# Acute cases: Small localized chondral lesion

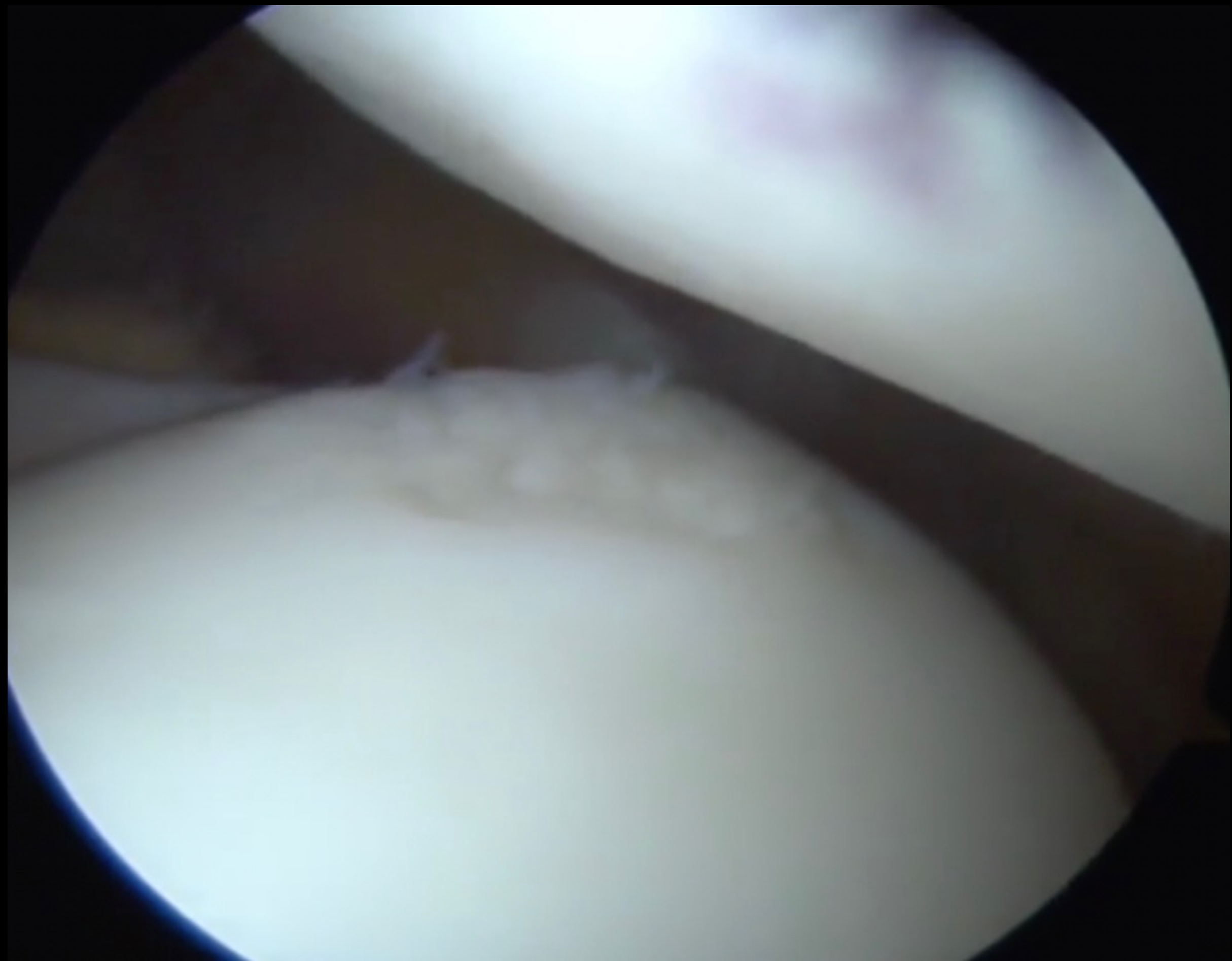
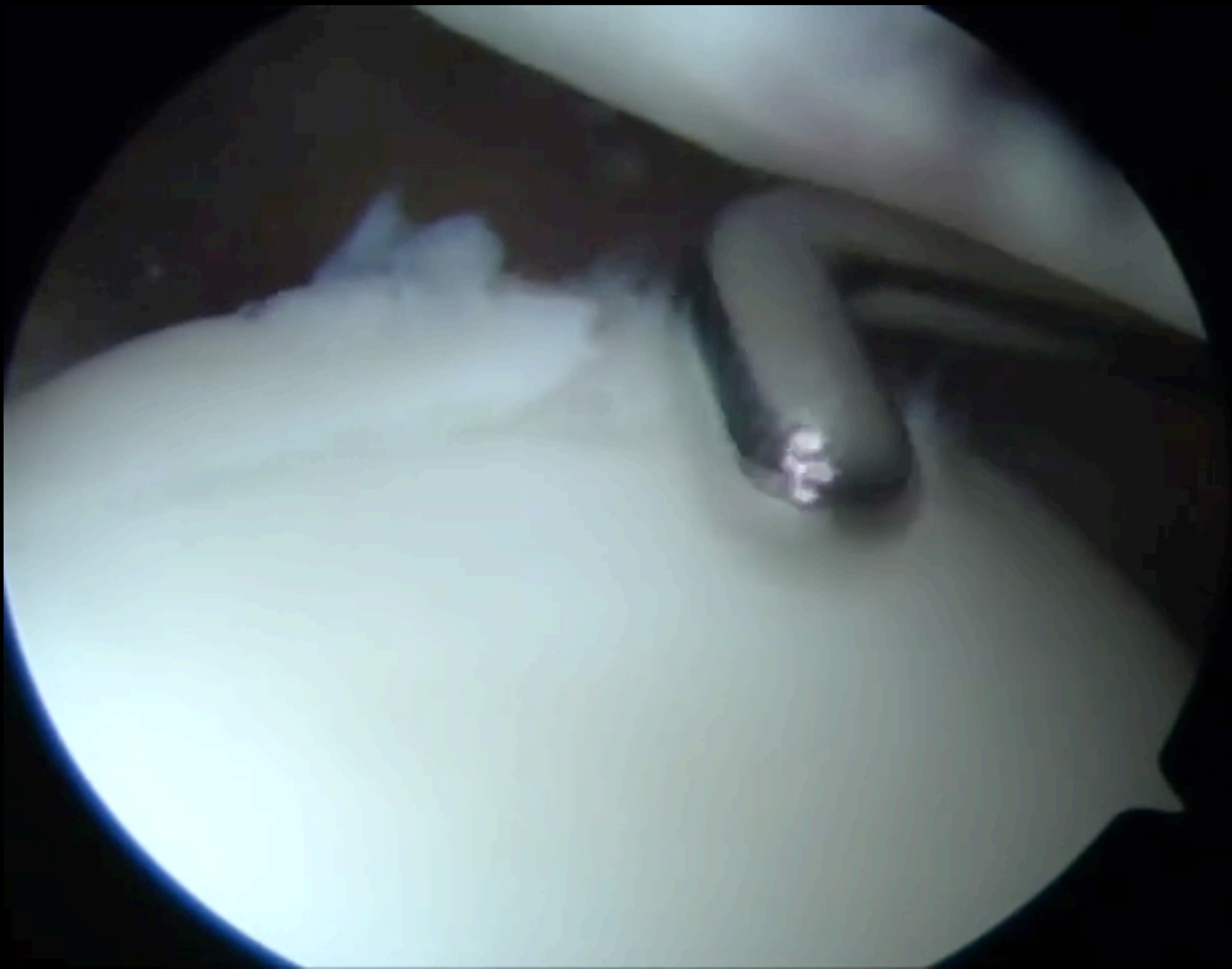
- Usually, simple debridement
- Microfracture
- Nanofracture







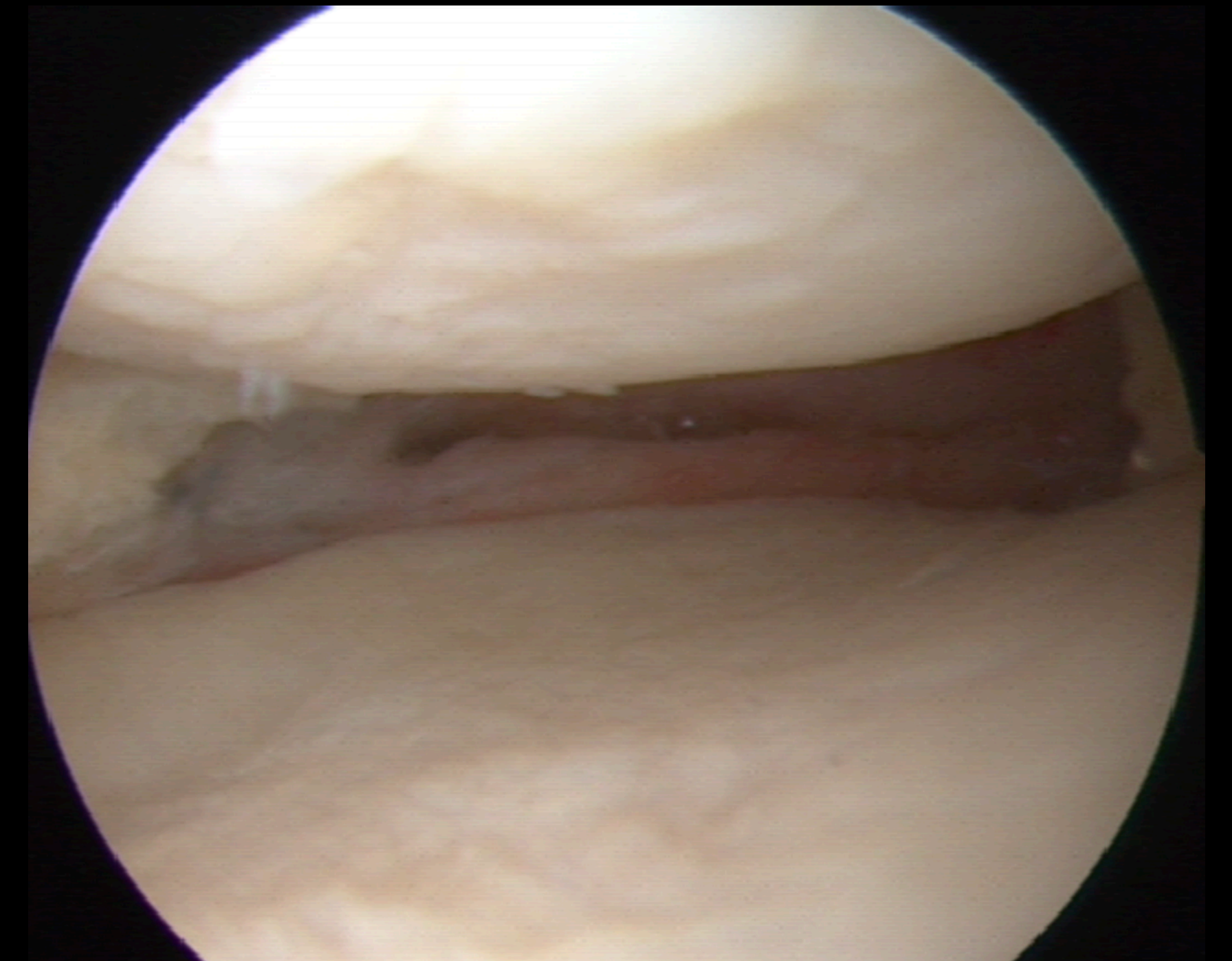
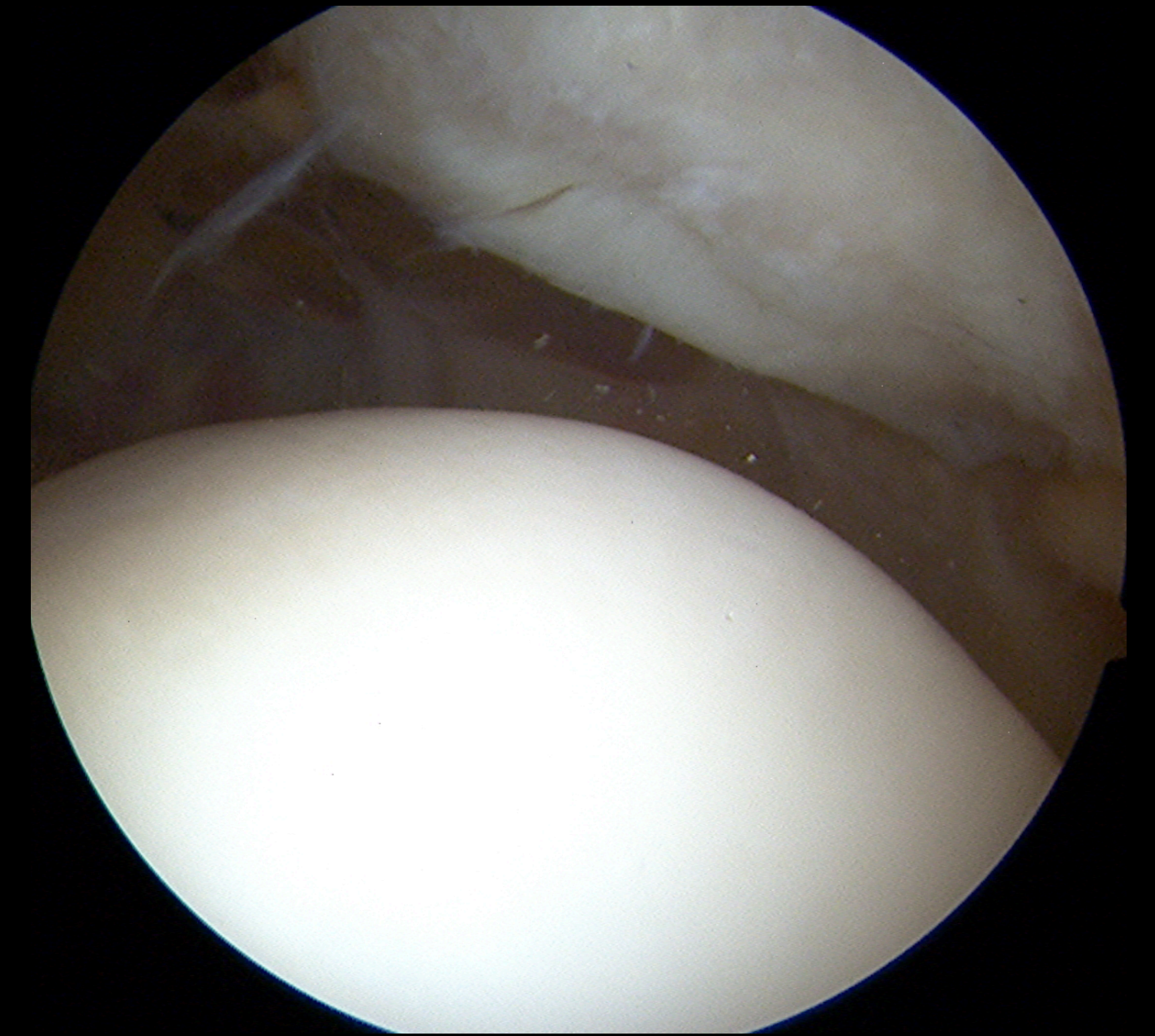






# Chronic cases

- The main treatment for chronic PF cartilage lesion is correction of instability to unload the damaged cartilage.

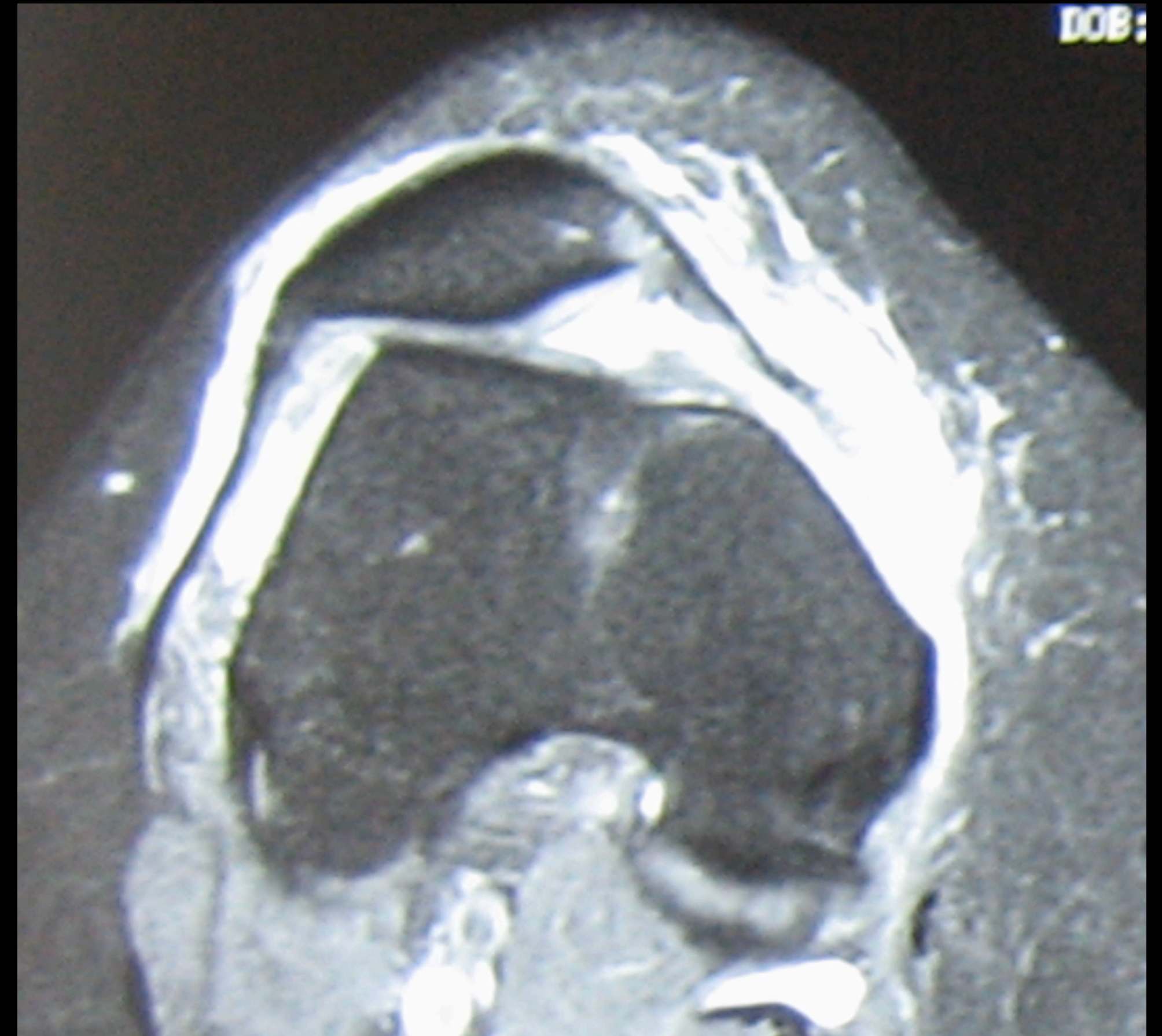



# Chronic cases

- The main treatment for chronic PF cartilage lesion is correction of instability to unload the damaged cartilage.

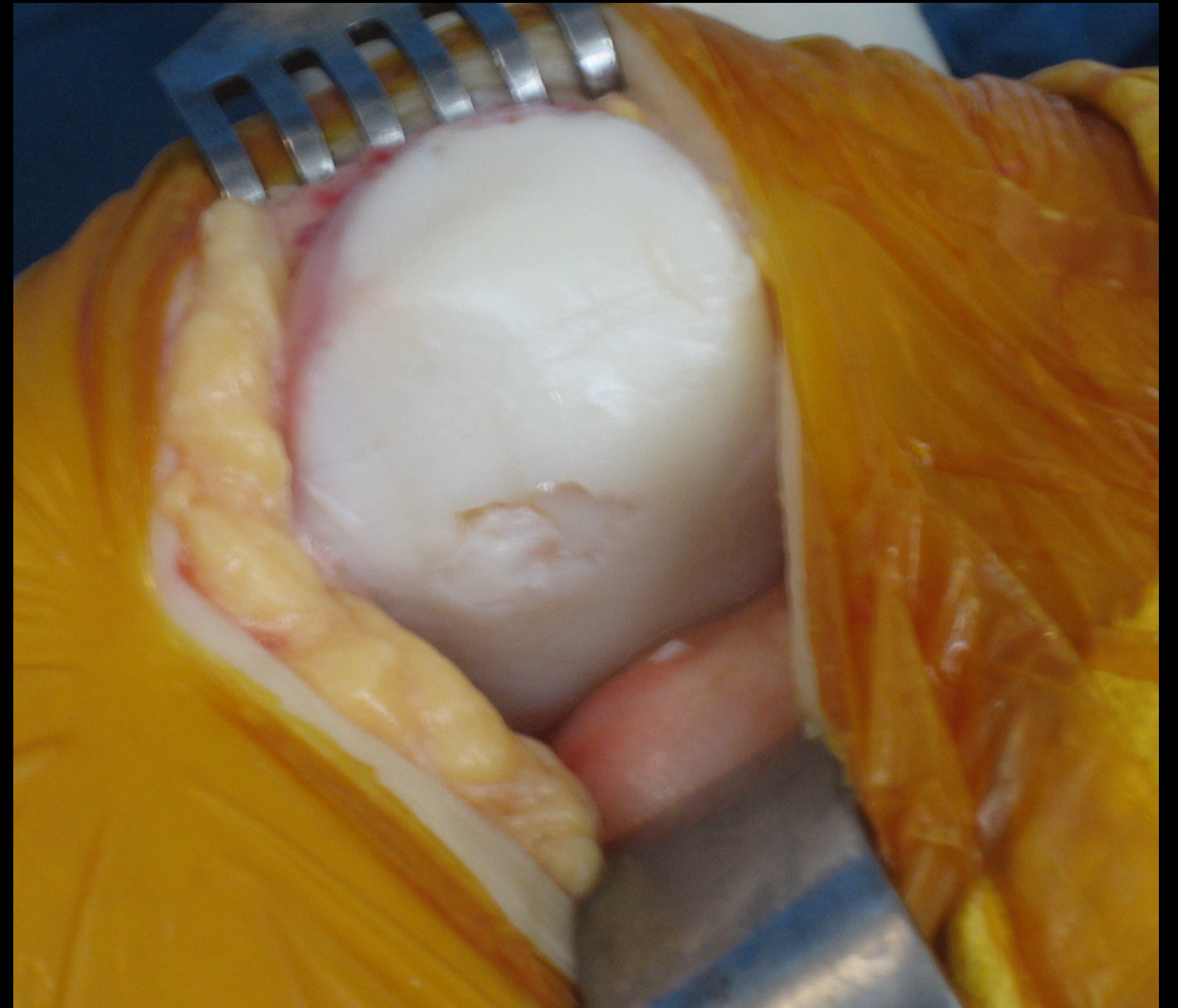Like HTO





# Chronic cases

- In some selected cases, consider to treat the cartilage lesion in the same time
- Particularly if the patient is young

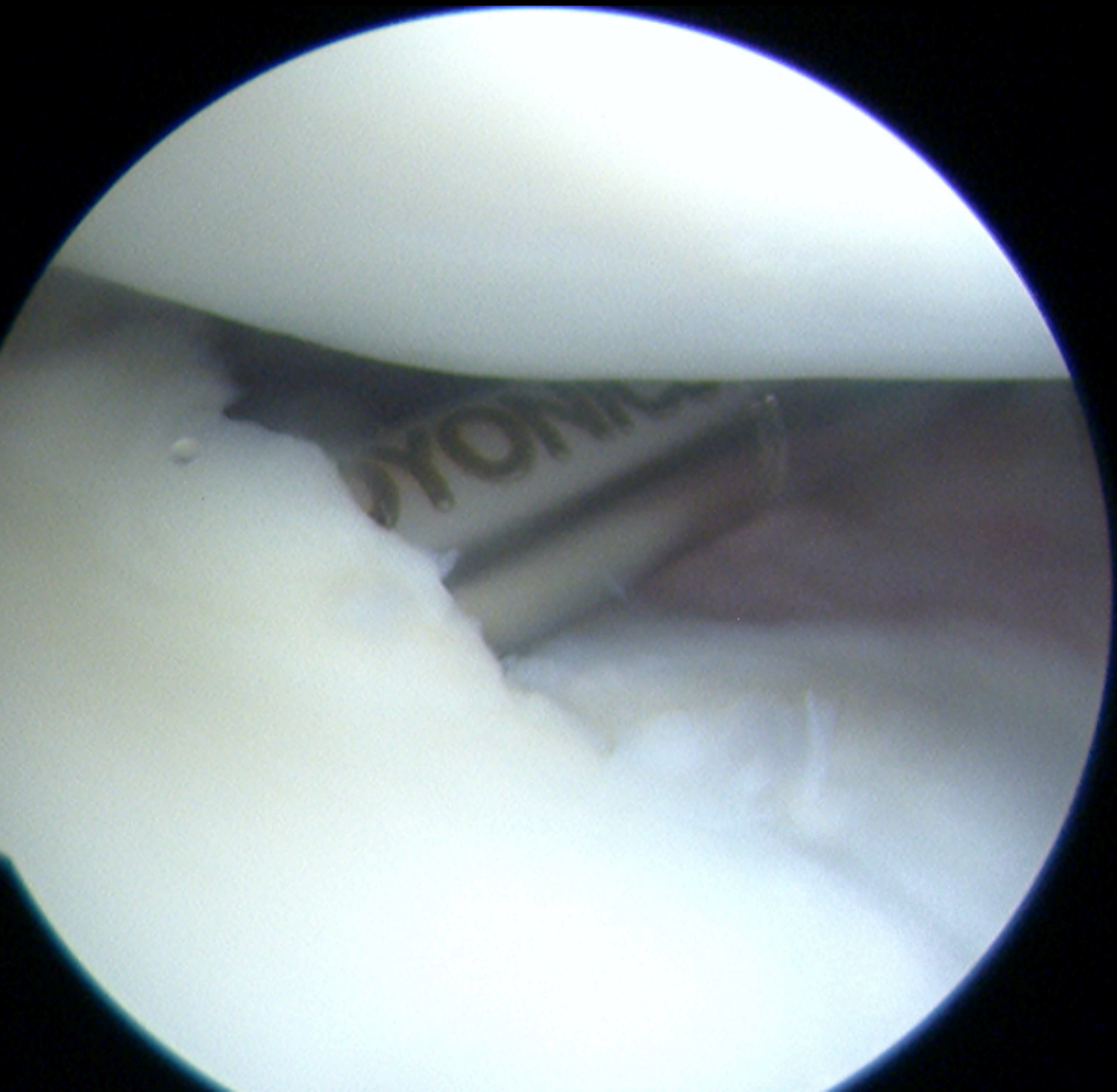




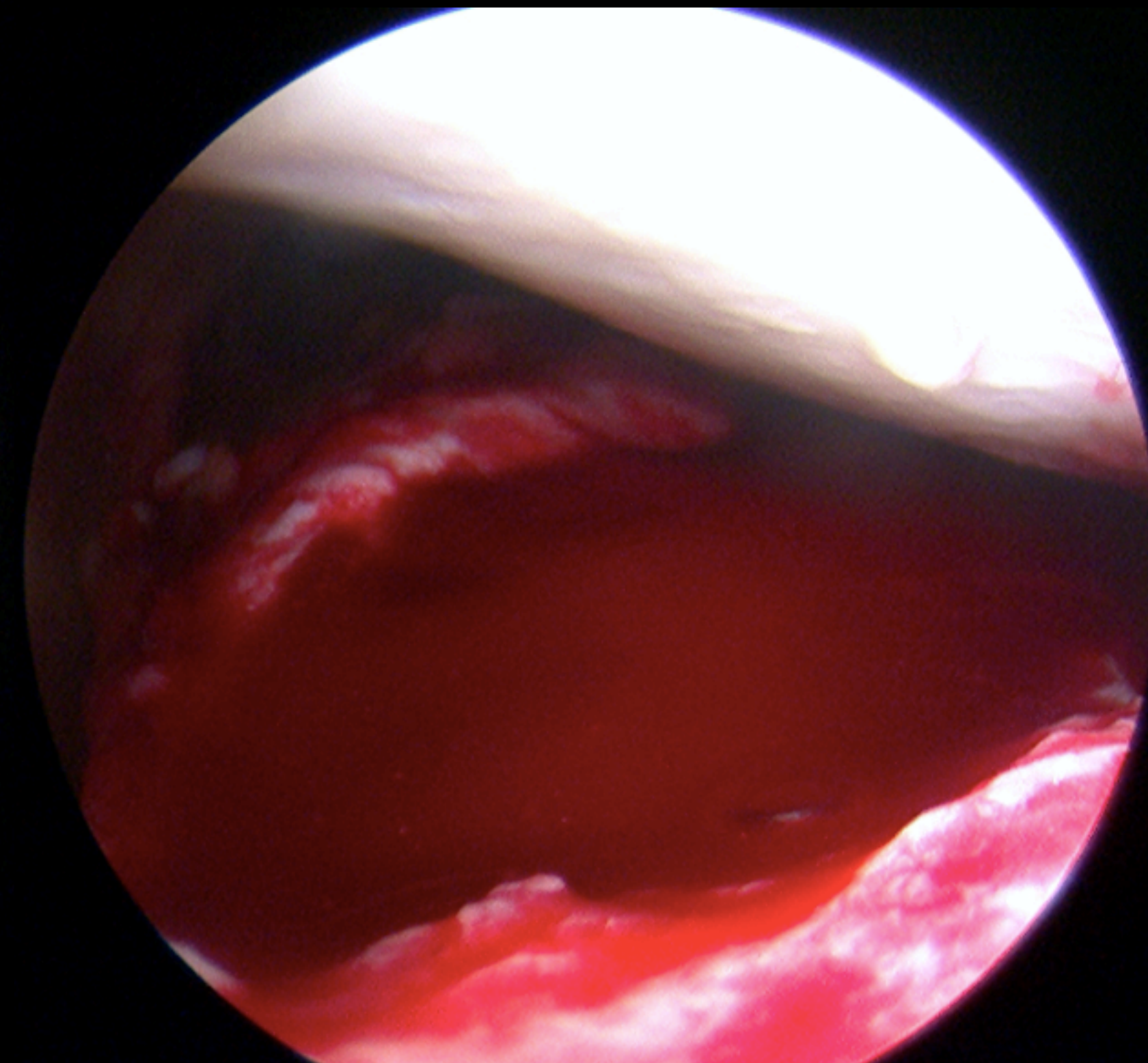
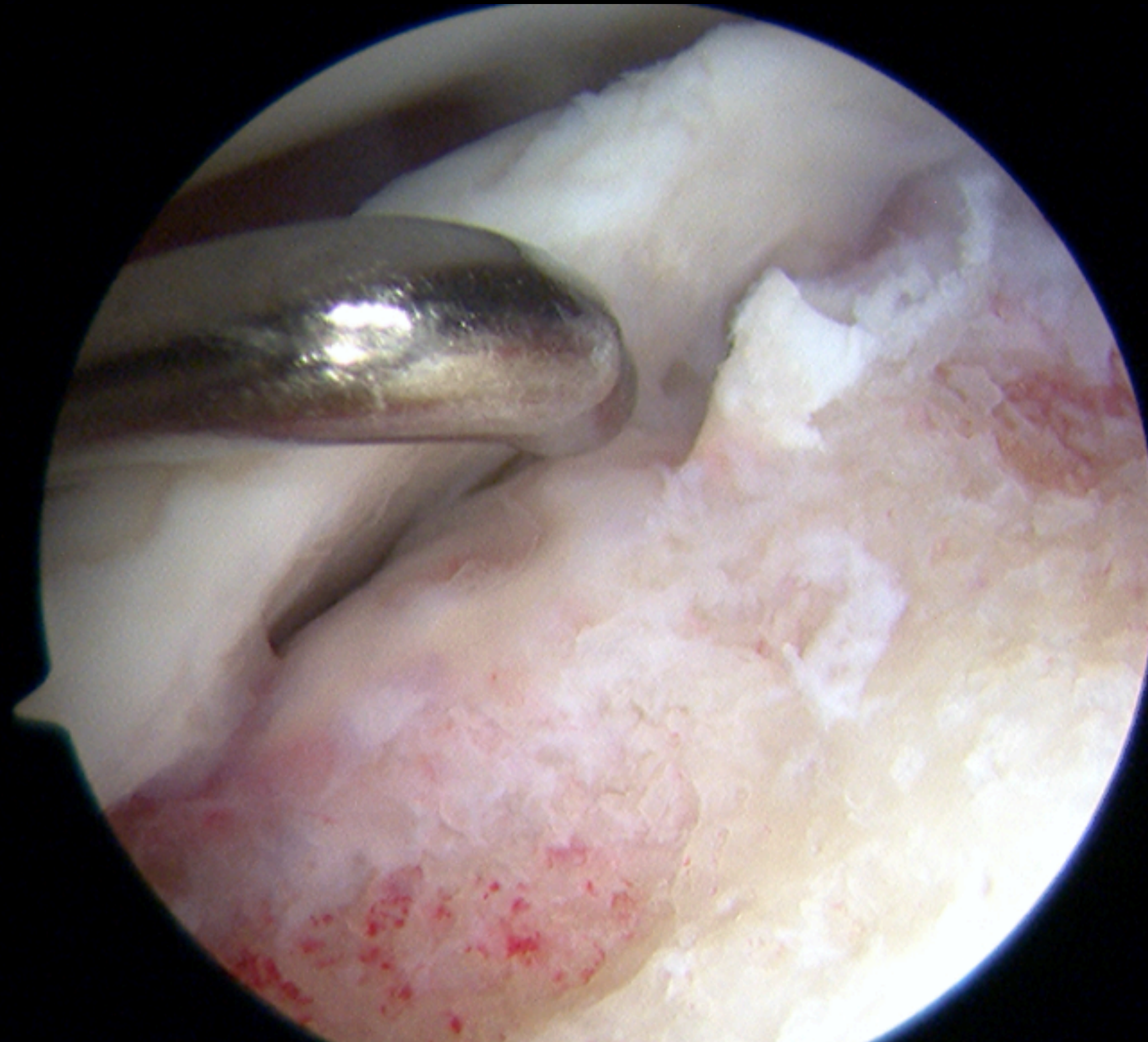
# Different cartilage repair techniques

BST Cargel

Shive et al.

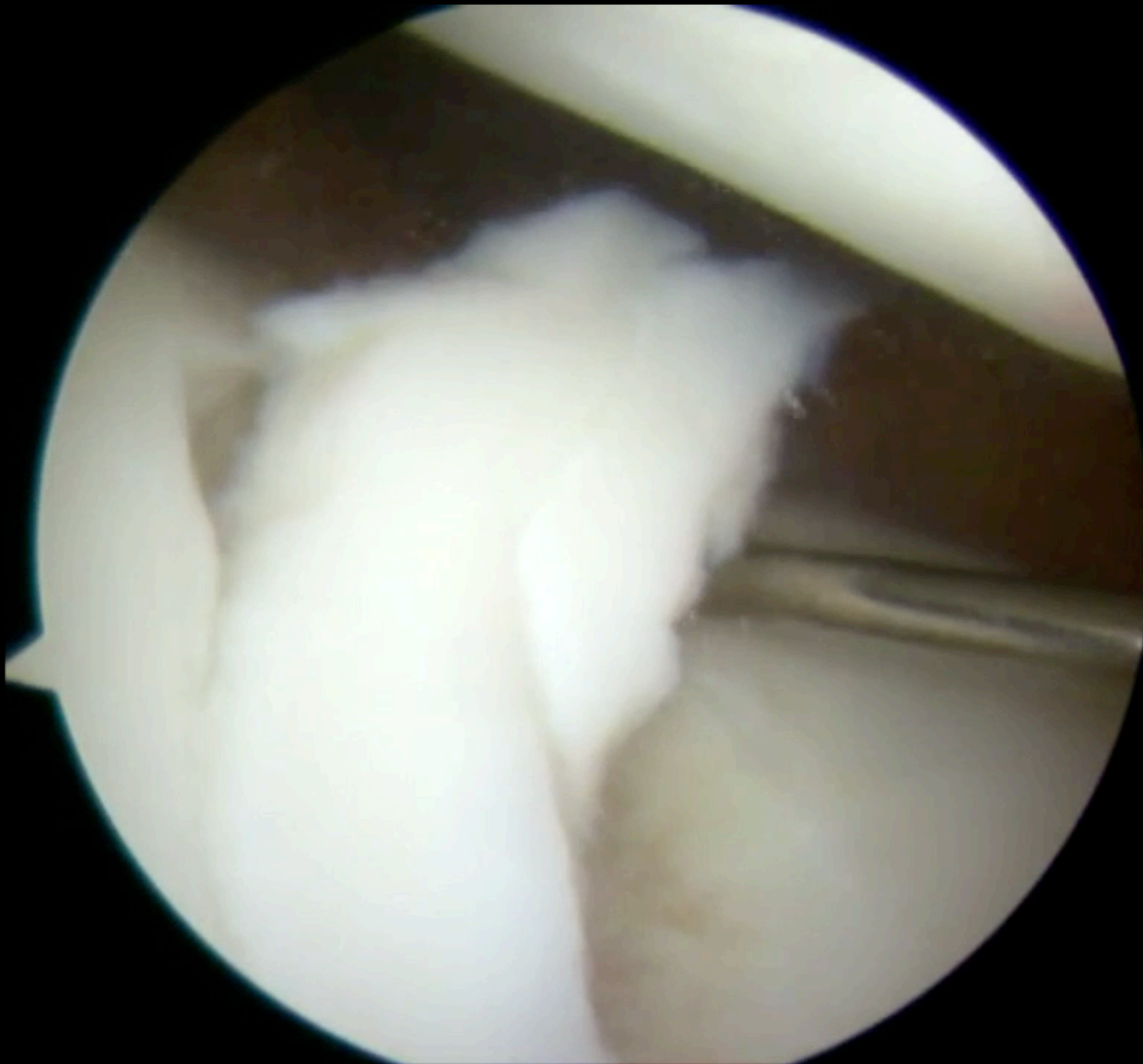

14 yo male



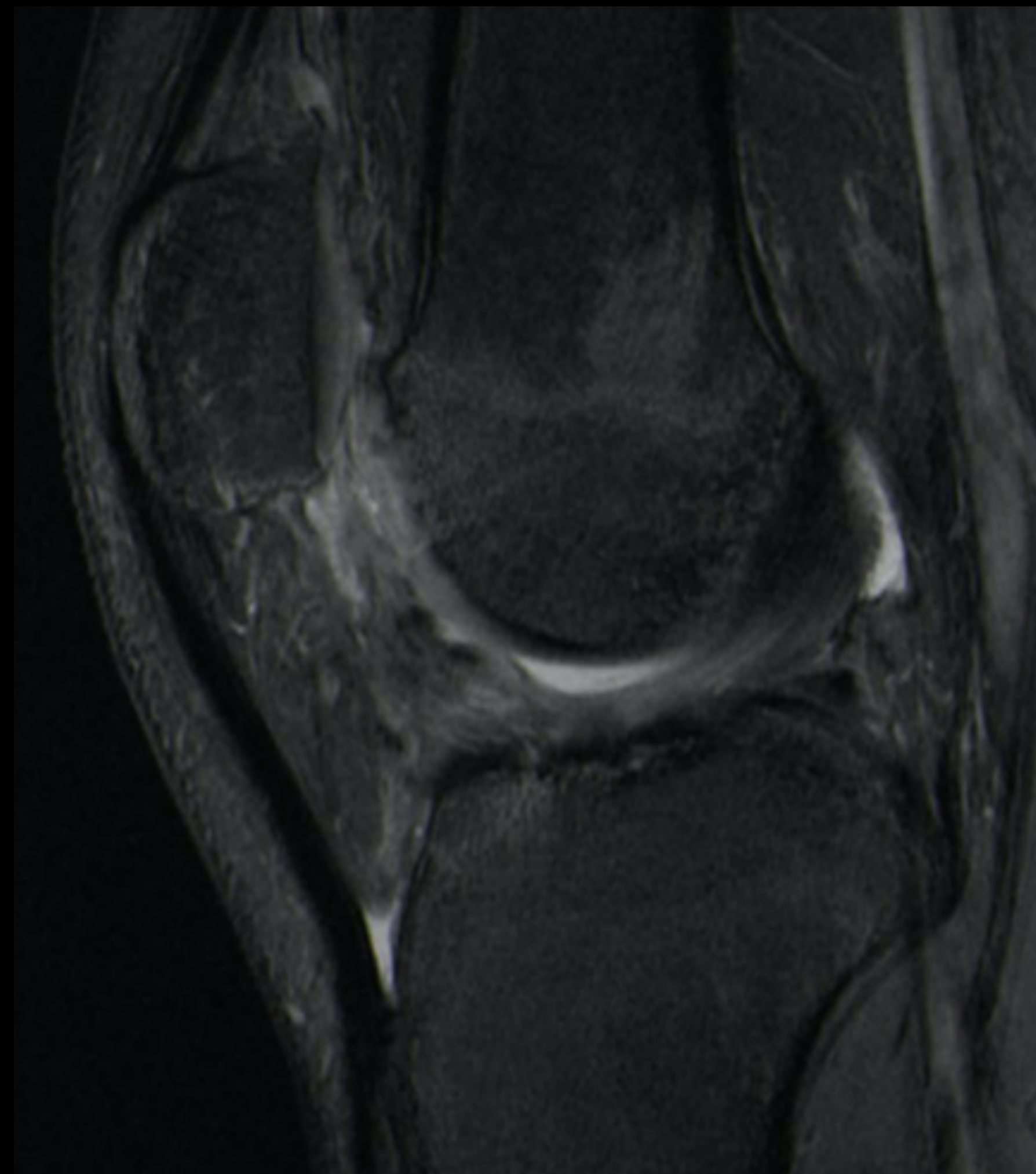
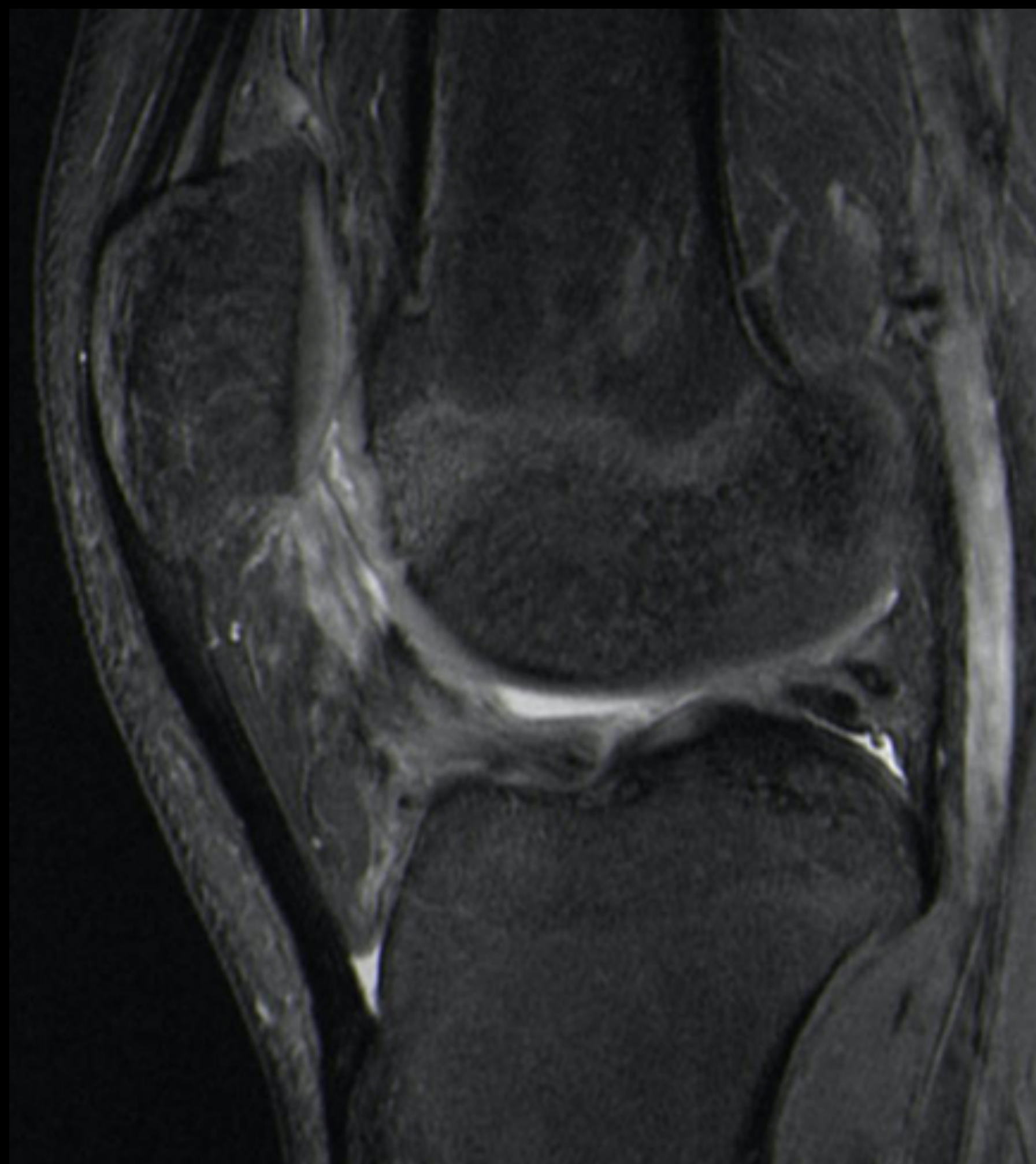


Hyalofast





4 months

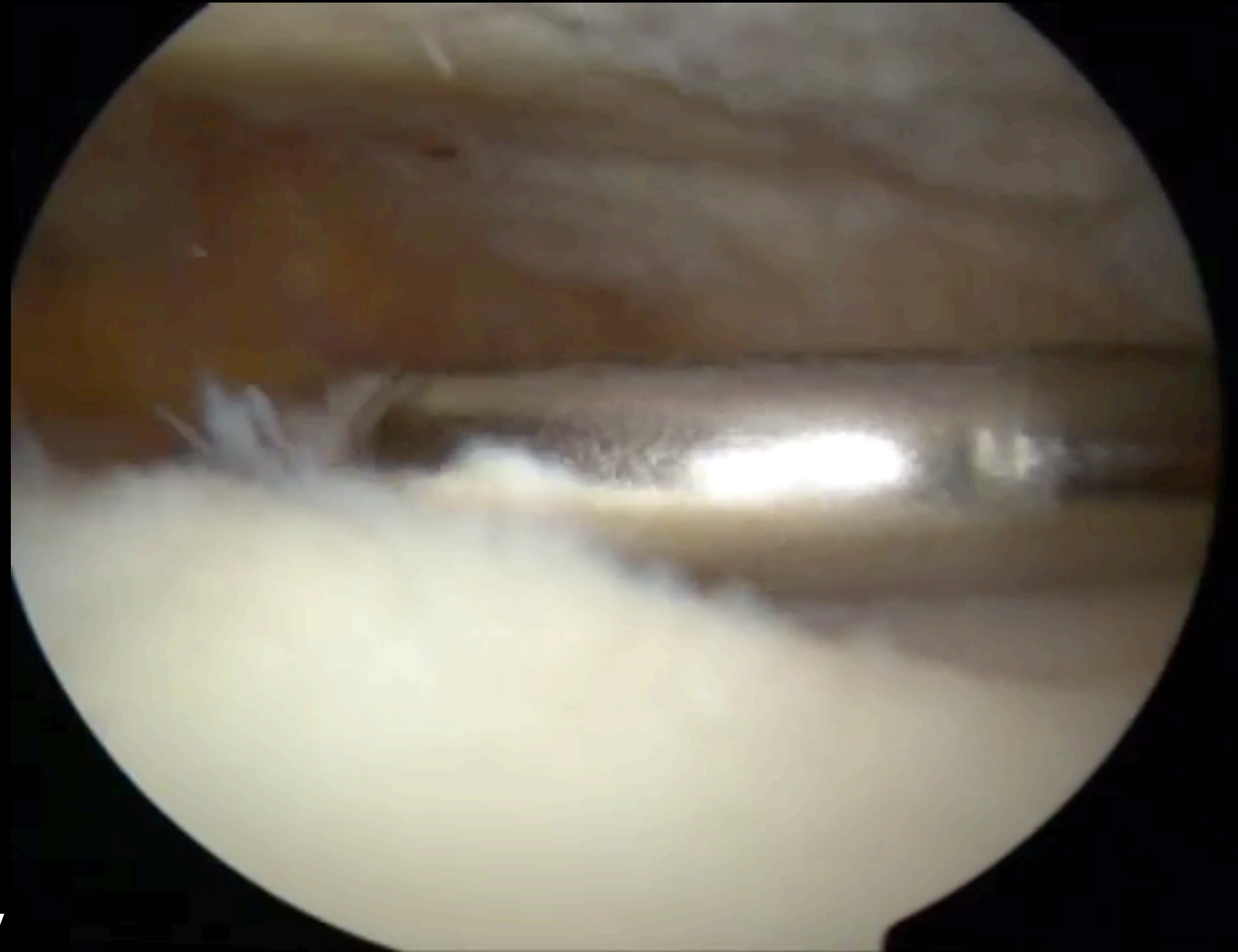




# Chronic cases: Diffuse cartilage lesion

- Usually only correction of deformity to unload the pathologic cartilage area

55 yo Female  
Chronic PF instability  
and pain





# How I deal with cartilage and osteochondral defects in patellofemoral instability

- **Acute cases**

- Loose chondral or osteochondral fragment: resection or fixation
- Small acute chondral lesion: debridement + TTT of patella instability
- Voluminous chondral lesion: repair + TTT of patella instability

- **Chronic cases**

- Localised lesion: consider cartilage repair
- Diffuse lesion: TTT of patella instability +/- debridement